



## ***Gastrocnemius Strain: A Case Study***

**Dr. Arif Rizvi<sup>1</sup>, Dr. Sumit Asthana<sup>2</sup>, Dr. Anuj Dwivedi<sup>3</sup>, Dr. Tahzeeb Fatima<sup>4</sup>,  
Wahida Khan<sup>5</sup>, Rutba Raheed<sup>6</sup>**

<sup>1,4</sup> Assistant Professor, E.I.A.H. Sc. & R, Era University, Lucknow

<sup>3</sup> Assistant Professor, Dept. of Physiotherapy, SCPM College of Nursing and Paramedical Science, Gonda

<sup>2</sup> Associate Professor & Head, E.I.A.H. Sc. & R, Era University, Lucknow

<sup>5</sup> Senior Lecturer, E.I.A.H. Sc. & R, Era University, Lucknow

<sup>6</sup> Physiotherapist

**Article Info: Received: 11-01-2024 / Revised: 18-02-2024 / Accepted: 24-03-2024**

**Address for correspondence: Dr. Arif Rizvi**

**DOI: <https://doi.org/10.32553/jbpr.v13i2.1095>**

**Conflict of interest statement: No conflict of interest**

### **Abstract:**

*Gastrocnemius Strain* is a painful condition of partial tearing of the medial belly of the gastrocnemius, caused by overstretching the muscle by concomitant ankle dorsiflexion and full knee extension. Contributory factors are muscle fatigue and degenerative changes [1].

The purpose of the case study is to present a case of *Gastrocnemius Strain*, who underwent physiotherapy department. The 35 years male was having pain in the left calf muscle for last eight days. According to the patient the pain started while running in the field for practicing for an upcoming sports event. He felt sudden acute pain in the left leg, followed by swelling after he placed his left heel on the field. He went to consult a physiatrist in a private hospital nearby. During examination, in clinic there was swelling, tenderness around the middle & lower part of left Gastrocnemius muscle. There was increase pain in the leg during dorsiflexion of left foot, both active & passive. He was unable bear full weight on the affected limb. Measurement of right & left Gastrocnemius muscle was 38 cm & 40 cm respectively, from 8 cm below tip of patella. The Thompson squeeze test was negative though it was painful. He was walking in non-weight bearing pattern using walker. M.R.I report suggested, there was fluid collection in left calf muscle, between Soleus & medial head of Gastrocnemius, most prominent at the myotendinous junction. There was also tear with oedema in anterior fibres of left mid & distal part of lateral head of Gastrocnemius & anterior fibres of distal part of medial head of Gastrocnemius. The patient was treated with low-level laser therapy for 15 sittings & was advised to apply Cryotherapy followed by crepe bandage application. After completion of treatment, there was minimum tenderness or pain in the affected area. The patient was able to bear full weight on the left limb. He was advised to continue exercises for strengthening Gastrocnemius & Soleus muscle at home as demonstrated. Pain was measured using V.A.S on the first day before & last day after treatment.

**Keywords:** *Gastrocnemius Strain*, low-level laser therapy, clinical case, calf muscle injury, Cryotherapy.

## Introduction

Muscle tears located in the calf region are often associated with other pathologies such as thrombophlebitis, soleus tear, Achilles tendon rupture, and posterior compartment syndrome, making it more difficult for the practitioner to formulate a correct diagnosis, despite performing an accurate clinical examination [1]. Research say that conservative management is effective in the treatment of gastrocnemius tears [2, 3, 4].

Calf muscle tear injury, also termed “tennis leg”, is a relatively common clinical condition involving damage to the medial head of the gastrocnemius muscle. Understanding the epidemiology and obtaining a comprehensive clinical history can aid in the diagnosis. The physical exam, including observation, palpation, orthopedic testing, and gait analysis, allows the practitioner to localize the area of injury and asses the severity of soft tissue damage. Both diagnostic ultrasound and MRI imaging allow therapists to rule out other pathologies and provide useful information to direct therapeutic management [4].

The diagnosis of the gastrocnemius tear is often clinical [4, 5].

Tennis leg is a term that was coined in 1883 by Powell [6]. It was initially attributed to isolated rupture of the plantaris muscle or tendon, however it was subsequently established that it occurs due to a complete or partial tear of the medial head of gastrocnemius muscle either alone or in combination with soleus or plantaris. The condition is most commonly seen in middle

aged individuals who participate in racquet sport, running or any such sporting activity. The injury occurs due to partial contraction of the gastrocnemius muscle with concomitant overstretching of the muscle due to knee extension resulting in disruption of fibres from the aponeurosis [7].

### Causes

**a) Weak/Deconditioned muscle:** The weak or deconditioned muscles are likely to rupture than conditioned and stretched muscles.

**b) History of past injury:** Previously injured tissues if healed with fibrotic tissues can get injured easily.

**c) Age factor:** Middle aged persons can develop Tennis leg because of degeneration of muscle fibres due to increased age & mostly medial calf muscles are injured [8].

There is a consensus to classify myotendinous strains as first degree (Stretch injury), second degree (Partial tear), and third degree (Complete rupture) [4, 9]. This type of classification takes into consideration the physical findings and pathological correlation as described above, and the disabilities that is, absent, mild, or complete loss of muscle function [10, 11]. The term strain does not accurately reflect the structural characteristics of injuries of muscles; rather it is more of a biomechanical description of the mechanism of injury, and as such, the term tear should be used as it more accurately describes the structural injuries of muscle fibres [12]

## Classification

Table 1:

Comprehensive muscle injury classification: type-specific definitions and clinical presentations						
Type	Classification	Definition	Symptoms	Clinical signs	Location	Ultrasound/MRI
1A	Fatigue-induced muscle disorder	Circumscribed longitudinal increase of muscle tone (muscle firmness) due to overexertion, change of playing surface or change in training patterns	Aching muscle firmness. Increasing with continued activity. Can provoke pain at rest. During or after activity	Dull, diffuse, tolerable pain in involved muscles, circumscribed increase of tone. Athlete reports of 'muscle tightness'	Focal involvement up to entire length of muscle	Negative
1B	Delayed-onset muscle soreness (DOMS)	More generalised muscle pain following unaccustomed, eccentric deceleration movements.	Acute inflammatory pain. Pain at rest. Hours after activity	Oedematous swelling, stiff muscles. Limited range of motion of adjacent joints. Pain on isometric contraction. Therapeutic stretching leads to relief	Mostly entire muscle or muscle group	Negative or oedema only
2A	Spine-related neuromuscular muscle disorder	Circumscribed longitudinal increase of muscle tone (muscle firmness) due to functional or structural spinal lumbopelvic disorder.	Aching muscle firmness. Increasing with continued activity. No pain at rest	Circumscribed longitudinal increase of muscle tone. Discrete oedema between muscle and fascia. Occasional skin sensitivity, defensive reaction on muscle stretching. Pressure pain	Muscle bundle or larger muscle group along entire length of muscle	Negative or oedema only
2B	Muscle-related neuromuscular muscle disorder	Circumscribed (spindle-shaped) area of increased muscle tone (muscle firmness). May result from dysfunctional neuromuscular control such as reciprocal inhibition	Aching, gradually increasing muscle firmness and tension. Cramp-like pain	Circumscribed (spindle-shaped) area of increased muscle tone, oedematous swelling. Therapeutic stretching leads to relief. Pressure pain	Mostly along the entire length of the muscle belly	Negative or oedema only

3A	Minor partial muscle tear	Tear with a maximum diameter of less than muscle fascicle/bundle.	Sharp, needle-like or stabbing pain at time of injury. Athlete often experiences a 'snap' followed by a sudden onset of localised pain	Well-defined localised pain. Probably palpable defect in fibre structure within a firm muscle band. Stretch-induced pain aggravation	Primarily muscle-tendon junction	Positive for fibre disruption on high resolution MRI*. Intramuscular haematoma
3B	Moderate partial muscle tear	Tear with a diameter of greater than a fascicle/bundle	Stabbing, sharp pain, often noticeable tearing at time of injury. Athlete often experiences a 'snap' followed by a sudden onset of localised pain. Possible fall of athlete	Well-defined localised pain. Palpable defect in muscle structure, often haematoma, fascial injury Stretch-induced pain aggravation	Primarily muscle-tendon junction	Positive for significant fibre disruption, probably including some retraction. With fascial injury and intermuscular haematoma
4	(Sub)total muscle tear/tendinous avulsion	Tear involving the subtotal/complete muscle diameter/tendinous injury involving the bone-tendon junction	Dull pain at time of injury. Noticeable tearing. Athlete experiences a 'snap' followed by a sudden onset of localised pain. Often fall	Large defect in muscle, haematoma, palpable gap, haematoma, muscle retraction, pain with movement, loss of function, haematoma	Primarily muscle-tendon junction or Bone-tendon junction	Subtotal/complete discontinuity of muscle/tendon. Possible wavy tendon morphology and retraction. With fascial injury and intermuscular haematoma
Contusion	Direct injury	Direct muscle trauma, caused by blunt external force. Leading to diffuse or circumscribed haematoma within the muscle causing pain and loss of motion	Dull pain at time of injury, possibly increasing due to increasing haematoma. Athlete often reports definite	Dull, diffuse pain, haematoma, pain on movement, swelling, decreased range of motion, tenderness to palpation depending on the severity	Any muscle, mostly vastus intermedius and rectus femoris	Diffuse or circumscribed haematoma in varying dimensions

			external mechanism	of impact. Athlete may be able to continue sport activity rather than in indirect structural injury		
--	--	--	--------------------	---	--	--

### Signs and symptoms

1. Sudden onset of pain, often radiating to ankle.
2. Swelling.
3. Tenderness localized to the musculotendinous junction of the head of the gastrocnemius.
4. Palpable defect in the medial belly of the gastrocnemius just above the musculotendinous junction.
5. Tendo-Achilles should be intact in palpation.
6. Inability to bear weight on the affected limb.
7. Distal arterial pulses should be palpable.

### Complications

Compartmental syndrome [13].

### Differential diagnosis

- Ruptured Baker's cyst.
- Tennis leg.
- Tear of tendoachilles.
- Arthritis.
- Pyomyositis
- Abscess.
- Infection.
- Haematoma.
- Bursitis.
- Stress fracture.
- Thrombophlebitis.
- Aneurysm.
- Arteriovenous malformation.
- Compartment syndrome.
- Foreign body.
- Tumor [14].

### Investigations

- X-ray.
- M.R.I.
- U.S.G.
- Color Doppler.

### Treatment

*Gastrocnemius Strain* in acute stage is generally treated by following PRICE protocol i.e protection from further injury, rest, ice compression, elevation of affected part to relieve swelling. NSAIDS are prescribed for controlling pain & inflammation. Electrotherapy a branch of Physiotherapy can be started with applications of pain relieving modalities like I.F.T, T.E.N.S, and use of L.L.L.T or U.S.T to improve healing process. Once pain & inflammation subsides, stretching of injured muscle, improvement of muscle power with resistive exercises help in performing ADLs in normal way. Swimming & pool therapy often hastens recovery process.

### Prognosis

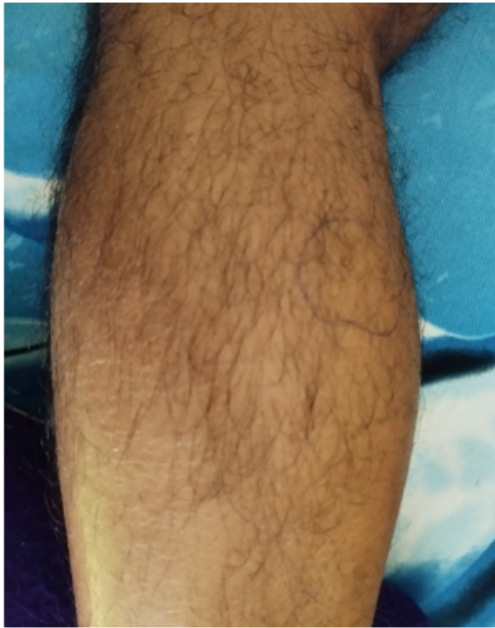Prognosis is often good in case of early diagnosis and treatment. However misdiagnosis, non-compliance to treatment can delay process of recovery.

### Case study

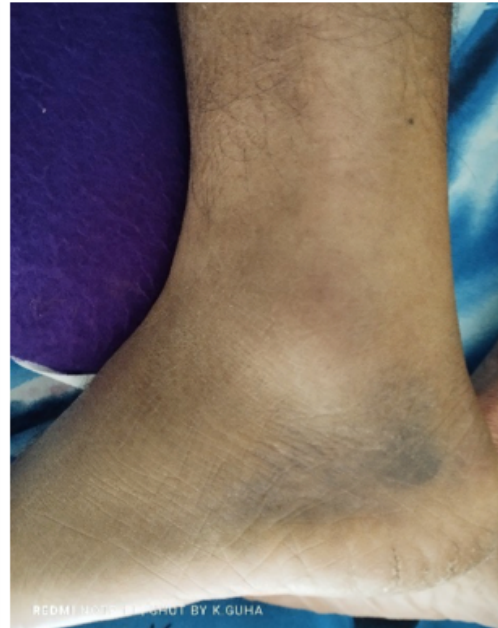A 52 years male came with complain of pain in the left calf muscle for last seven days. According to the patient the pain started while running in the field for practicing for an upcoming sports event. He felt sudden acute pain in the left leg, followed by swelling after he placed his left heel on the

field. He went to consult a physiatrist in a private hospital nearby. During examination, in clinic there was swelling, tenderness around the middle & lower part of left Gastrocnemius muscle. There was increase pain in the leg during dorsiflexion of left foot, both active & passive. Few bruise marks were also seen on the medial aspect of left foot. He was unable bear full weight on the affected limb. Measurement of right & left Gastrocnemius muscle was 38 c.m & 40 c.m respectively, from 8 c.m below tip of patella. The Thompson squeeze test was negative

though it was painful. He was walking in non-weight bearing pattern using walker. M.R.I report suggested, there was fluid collection in left calf muscle, between Soleus & medial head of Gastrocnemius, most prominent at the myotendinous junction. There was also tear with oedema in anterior fibres of left mid & distal part of lateral head of Gastrocnemius & anterior fibres of distal part of medial head of Gastrocnemius. The patient was treated with L.L.L.T for 15 sittings & was advised to apply Cryotherapy followed by crepe bandage application.



**Fig 1: Swelling**



**Fig 2: Bruise marks**

Dosage of laser used  
Frequency- 6000 Hz.  
Mode- Pulsed mode (80%).

### Result

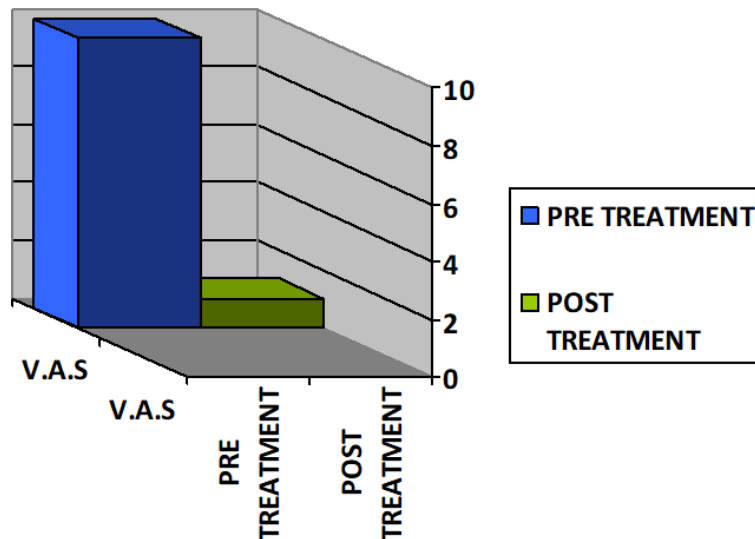
After completion of treatment, there was minimum tenderness or pain in the affected area. The patient was able to bear full weight on the left limb. He was advised to continue exercises for strengthening & stretching of

Time- 6 minutes per point (three points).

Area- 1cm<sup>2</sup>.

Energy density- 17.27 J/cm<sup>2</sup>.

Gastrocnemius & Soleus muscle at home as demonstrated. Pain was measured using V.A.S on the first day before & last day after treatment. On the first day V.A.S score was 10 before starting of treatment on first day and on 15th day after treatment V.A.S score was 1



### Discussion

In this case it has been seen that *Gastrocnemius Strain* can be treated successfully if diagnosed & treated early. Do's & don'ts should also be explained properly to the patient & care givers. There are many modes of treatment available in physiotherapy. But in this case L.L.L.T was used successfully to cure Tennis leg. L.L.L.T was effective in treating this condition. In the beginning before starting of treatment V.A.S was 10, whereas on 15th day post-treatment V.A.S was 1. Laser therapy has a powerful anti-inflammatory effect that reduces or eliminates pain. It can accelerate the healing process by increasing circulation to the area, moving out inflammatory proteins and helps to supply nutrients and improve blood flow. It has been effectively used in healing of injured tissues for faster healing which causes early recovery. The patient was advised to continue exercises for strengthening & stretching of *Gastrocnemius* & *Soleus* muscle at home as demonstrated.

Home exercise program should also be demonstrated to the patient in presence of patient's family members or care givers for better understanding. Last but not the least;

periodic re-assessment should be done to avoid errors during treatment, if any.

### Conclusion

*Gastrocnemius Strain*, also termed "tennis leg", is a relatively common clinical condition involving damage to the medial head of the *Gastrocnemius* muscle. Collection & proper understanding of clinical history can help in diagnosis. The physical examination, including observation, palpation, and gait analysis, allows Physiotherapist to localize the area of injury. The possibility of an isolated tear of the medial *Gastrocnemius* tendon should be considered in a patient presenting with posterior lower leg pain and a palpable defect in the posterior aspect of the calf muscle.

Early intervention can help in early recovery from the injury. In acute stage the PRICE protocol i.e protection, rest, ice, compression, and elevation is important. Rehabilitation in the sub-acute phase facilitates the healing process and timely return to normal activities of daily living. In this case accurate diagnosis with early treatment helped the patient to recover from the soft tissue injury. L.L.L.T has been proved effective treatment for this condition by increasing circulation to the injured tissues, reducing inflammatory

process, supplying proteins, nutrients required for healing.

### References

1. Tennis Leg: Avrum I. Froimson, MD: JAMA. 1969;209(3):415-416: July 21, 1969.
2. Flecca D, et al. US evaluation and diagnosis of rupture of the medial head of the gastrocnemius (Tennis leg) J Ultrasound. 2007;10:194-198. PubMed.
3. Campbell J. Posterior calf injury. Foot Ankle Clin N Am. 2009;14(4):761-771. PubMed.
4. Armfield D, et al. Sports-related muscle injury in the lower extremity. Clin Sports Med. 2006;25:803-842. PubMed.
5. Kwak H, et al. Diagnosis and follow-up US evaluation of ruptures of the medial head of the gastrocnemius (Tennis Leg) Korean J Radiol. 2006;7:193-198. PubMed.
6. Powell RW. Lawn tennis leg. Lancet. 1883;2:44.
7. Spina AA. The plantaris muscle: anatomy, injury, imaging and treatment. J Can Chiropr Assoc. 2007;51:158-165. [PMC free article] PubMed.
8. Tennis leg: Prodyut Das: Physiotherapy-treatment.com.
9. Mueller-Wohlfahrt H, et al. Terminology and classification of muscle injuries in sport: The Munich consensus statement. Br J Sports Med. 2013;47:342-350. PubMed.
10. Bencardino J, et al. Traumatic musculotendinous injuries of the knee: diagnosis with MR Imaging. Radiographics. 2000;20:S103-20. PubMed.
11. Dixon J. Gastrocnemius vs. soleus strain: how to differentiate and deal with calf muscle injuries. Curr Rev Musculoskelet Med. 2009;2:74-77. PubMed.
12. Mueller-Wohlfahrt H, et al. Terminology and classification of muscle injuries in sport: The Munich consensus statement. Br J Sports Med. 2013;47:342-350. PubMed.
13. Bhatia M, Vinay Maurya J, Debnath, Gupta P. Tennis leg: A mimic of deep venous thrombosis: Med J Armed Forces India. 2019 Jul;75(3):344-346. Published online; c2017 Dec 7.
14. Useche JN, De Castro AM, Galvis GE. Use of US in the evaluation of patients with symptoms of deep venous thrombosis of the lower extremities. Radiographics. 2008;28:1785-1797. PubMed.