



Impact on Mental Health Problems during Cocksackievirus Outbreak in the General Public: A Review

Nishtha Singh*¹, Pratishta Singh², Shraddha Singh³

¹Assistant Professor, T.S. Misra University, Department of Microbiology

²Senior Resident, Ram Manohar Lohia Institute, Department of Psychiatry

³Head of Department, King George Medical University, Department of Physiology

Article Info: Received: 15-12-2024 / Revised: 30-12-2024 / Accepted: 11-01-2025

Corresponding Author: Dr. Nishtha Singh

DOI: <https://doi.org/10.32553/jbpr.v14i1.1225>

Conflict of interest statement: No conflict of interest

Abstract:

Cocksackievirus group B (CVB), a member of the *Picornaviridae* family and enterovirus genus, poses risks during pregnancy due to its potential to cause severe fetal and neonatal infections. Transmission primarily occurs through fecal–oral routes, with infections peaking mostly in warmer months. Vertical transmission to the fetus can lead to conditions such as myocarditis, encephalitis, and systemic neonatal disease, presenting clinically as severe myocardial syndromes and neurological deficits. Diagnostic challenges include detecting asymptomatic maternal infections and conducting in utero assessments using advanced techniques like RT-PCR from amniotic fluid samples should be encouraged. Morbidity and mortality associated with congenital CVB infections are notable. Current treatments are limited to supportive care, with emerging therapies showing promise but requiring further study for efficacy. Mental health impact due to this virus results in speech development failure and autistic feature. Future research should aim to fill knowledge gaps in epidemiology, improve diagnostic capabilities, and develop targeted interventions to enhance maternal and fetal outcomes and other health issues due to this virus.

Introduction

Cocksackievirus group B belongs to the family *Picornaviridae* and the genus enterovirus. Enteroviruses (EVs) are positive-sense, single-stranded RNA viruses, named for their gastrointestinal route of transmission [1]. These viruses are categorized based on their pathogenesis in humans and laboratory animals into four groups: polioviruses, coxsackie A viruses (CA), coxsackie B viruses (CB), and echoviruses [2]. Humans are the only known reservoir for coxsackieviruses A and B, which

spread through feco–oral and possibly respiratory routes [3]. The disease is generally mild and lasted less than a week in most cases, characterized by fever, a blister-like rash on the hands and feet, and oral ulcers caused by ruptured blisters in the mouth [4]. Group A coxsackieviruses typically cause flaccid paralysis due to generalized myositis. In contrast, group B coxsackieviruses are associated with spastic paralysis, resulting from neuronal tissue degeneration and focal muscle

injury. They are also known to cause systemic neonatal infection, characterized by multiorgan involvement, one of the most potentially fatal conditions associated with enterovirus [5,6]. Clinicians diagnosed the suspected patient as a confirmed case of Hand Foot and Mouth Disease (HFMD) based on epidemiological history, clinical manifestations, and laboratory nucleic acid test [7]. These viruses are also known to cause mental health issues leading to speech development disorder, lack of interaction and social involvement. Further studies are needed to see their impact on society and among general public population.

Epidemiological Characteristics

The viral particle of EVs is symmetrical icosahedron composed of 60 subunits of coat protein and a single-stranded RNA genome (7.5 kb) of positive polarity [8]. Physicochemical characteristics of EVs include resistance to organic solvents such as ether and chloroform and low temperature conditions, and sensitivity to high temperature, chlorinated disinfectants, formaldehyde and ultraviolet etc [9]. The incubation period of HFMD is mostly 2–10 days, with an average of 3–5 days. The progression of HFMD be divided into 5 stages (rash, neurological dysfunction, early stage of cardiopulmonary failure, cardiopulmonary failure, recovery), and most cases generally. Clinically, most cases have fever accompanied by rash on hands, feet, mouth, and buttocks [10]. The following 7 indicators are considered as risk factors of HFMD severity: (a) high fever; (b) nervous system involvement; (c) abnormal respiratory rate and rhythm; (d) circulatory dysfunction; (e) increased white blood cell count; (f) increased blood glucose; (g) increased blood lactate [11], [12].

Pathophysiology

The initiation of CVB infection entails three primary stages: the attachment of infectious virions to specific receptor proteins, internalization and uncoating of virions, and interaction of viral RNA with intracellular factors essential for virus replication and protein

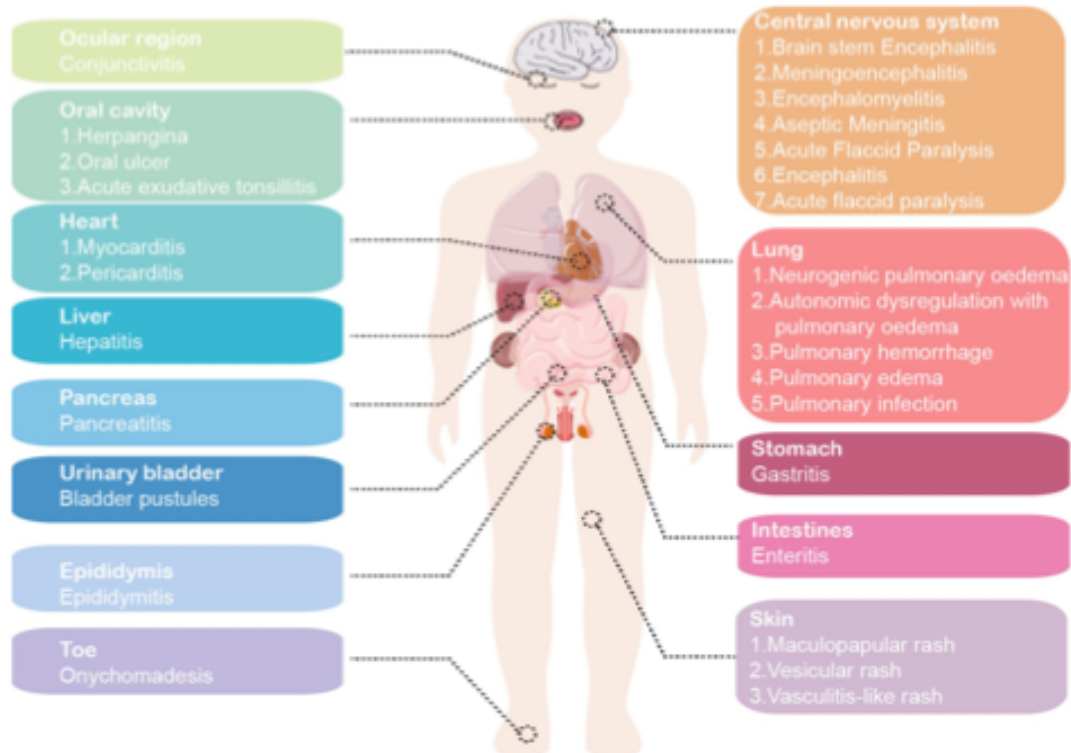
synthesis [13]. Coxsackievirus viruses are found to affect heart tissue and central nervous tissue. The transmission of enterovirus from the mother to the neonate typically occurs through contact with infected maternal secretions during vaginal delivery [14]. The diverse diseases caused by CVB, cellular and tissue tropism of nonenveloped viruses, the diverse diseases caused by CVB, encompassing acute and chronic myocarditis, aseptic meningitis, and pancreatitis, may encompass acute and chronic myocarditis, aseptic meningitis, and pancreatitis, may reflect variations in interactions with these cellular receptors [15]. Socioeconomic factors are also closely related to the epidemic of HFMD. The incidence of HFMD in urban residents, transportation hub cities, and economically developed areas compared to rural area, this is due to the higher population density and mobility in these areas [16], [17].

Effect on Mental Health Status

A substantial burden of neurological sequelae following HFMD has been given more attention, especially in severe cases [18], [19]. Among patients who experienced cardiopulmonary failure after CNS involvement, the proportion with subsequent sequelae (facial nerve palsy, limb weakness and atrophy, dysphagia, central hypoventilation, seizure, and psychomotor retardation) was significantly higher compared to those who only CNS involvement. The clinical severity of CNS involvement was significantly related to the children's neurodevelopment (a delay in the gross motor and personal-social categories, delayed neurodevelopment) [20], [21]. Serious virus-associated CNS infection during childhood appear to be associated with the later mental disorders, like attention-deficit hyperactivity disorder (ADHD) diagnosis alongside social/communication/emotion problems and autistic features [22],[23]. Long-term functional neurological morbidity is associated with the involvement of medulla oblongata, gray matter in the brainstem or spinal cord, which may be closely monitored for early intervention and

meticulous management. Long term consequences may be associated with speech disorder and poor health outcome. Severe HFMD occurs mainly affects preschool children under the age of five, a crucial stage in their growth and development [24]. More optimized monitoring programs have been developed and applied to estimate HFMD incidence and optimize serotype estimation. For common

cases, general treatment is usually used, isolating patients to avoid cross-infection, and taking good oral and skin care to avoid contamination. According to the development of HFMD, the treatment corresponding to the intervention of critical patients usually includes anti- viral therapy, immunoglobulin therapy, respiratory and circulatory system support, etc.



Conclusion

Enteroviruses exhibits a widespread distribution, with rare but severe outcomes. Their vertical transmission leads to conditions such as myocarditis and encephalitis. Diagnostic challenges persist, especially with asymptomatic maternal infections, relying on advanced techniques like RT-PCR. Treatment options are limited to supportive care and unproven antiviral therapies like Pleconaril, emphasizing the importance of preventive measures for transmission control. CVB infections present a serious threat to fetal and neonatal health as well as on the mental health of general public. While significant strides have been made in understanding the virus's pathophysiology and

transmission, considerable gaps remain in our knowledge, particularly regarding the incidence and long-term impact of congenital infections. Ongoing research and improved diagnostic, therapeutic, and preventive strategies are essential to address this public health concern effectively. More research and studies to be planned to see this virus impact on social and mental status of the individuals.

Conflict of Interest

Authors have no conflict of interest

Author Contribution

All authors contributed equally in drafting the manuscript

References

1. Kühl, U.; Pauschinger, M.; Noutsias, M.; Seeberg, B.; Bock, T.; Lassner, D.; Poller, W.; Kandolf, R.; Schultheiss, H.-P. High prevalence of viral genomes and multiple viral infections in the myocardium of adults with “idiopathic” left ventricular dysfunction. *Circulation* **2005**, *111*, 887–893. [[CrossRef](#)] [[PubMed](#)]
2. Romero, J.R. Enteroviruses. In *Clinical Virology, 3rd ed*; Richman, D.D., Whitley, R.J., Hayden, F.G., Eds.; American Society for Microbiology Press: Washington, DC, USA, 2009; pp. 1031–1062.
3. Konstantinidou, A.; Anninos, H.; Spanakis, N.; Kotsiakos, X.; Syridou, G.; Tsakris, A.; Patsouris, E. Transplacental infection of coxsackievirus B3 pathological findings in the fetus. *J. Med. Virol.* **2007**, *79*, 754–757. [[CrossRef](#)]
4. Alsop J, Flewett TH, Foster JR. “Hand-foot-and-mouth disease” in Birmingham in 1959. *Br Med J.* 1960;2(5214):1708–11.
5. Muehlenbachs, A.; Bhatnagar, J.; Zaki, S.R. Tissue tropism, pathology and pathogenesis of enterovirus infection. *J. Pathol.* **2014**, *235*, 217–228.
6. Increased Detections and Severe Neonatal Disease Associated with Coxsackievirus B1 Infection—United States. 2007. Available online: <https://www.cdc.gov/mmwr/preview/mmwrhtml/mm5720a4.htm> (accessed on 14 July 2024).
7. Xing W, Liao Q, Viboud C, Zhang J, Sun J, Wu JT, Chang Z, Liu F, Fang VJ, Zheng Y, Cowling BJ, Varma JK, Farrar JJ, Leung GM, Yu H. Hand, foot, and mouth disease in China, 2008–12: an epidemiological study. *Lancet Infect Dis.* 2014;14(4):308–18.
8. Plevka P, Perera R, Cardosa J, Kuhn RJ, Rossmann MG. Crystal structure of human enterovirus 71. *Science.* 2012;336(6086):1274.
9. Solomon T, Lewthwaite P, Perera D, Cardosa MJ, McMinn P, Ooi MH. Virology, epidemiology, pathogenesis, and control of enterovirus 71. *Lancet Infect Dis.* 2010;10(11):778–90.
10. Li XW, Ni X, Qian SY, Wang Q, Jiang RM, Xu WB, Zhang YC, Yu GJ, Chen Q, Shang YX, Zhao CS, Yu H, Zhang T, Liu G, Deng HL, Gao J, Ran XG, Yang QZ, Xu BL, Huang XY, Wu XD, Bao YX, Chen YP, Chen ZH, Liu QQ, Lu GP, Liu CF, Wang RB, Zhang GL, Gu F, Xu HM, Li Y, Yang T. Chinese guidelines for the diagnosis and treatment of hand, foot and mouth disease (2018 edition). *World J Pediatr.* 2018;14(5):437–47.
11. Solomon T, Lewthwaite P, Perera D, Cardosa MJ, McMinn P, Ooi MH. Virology, epidemiology, pathogenesis, and control of enterovirus 71. *Lancet Infect Dis.* 2010;10(11):778–90.
12. Huang J, Liao Q, Ooi MH, Cowling BJ, Chang Z, Wu P, Liu F, Li Y, Luo L, Yu S, Yu H, Wei S. Epidemiology of recurrent hand, foot and mouth disease, China, 2008–2015. *Emerg Infect Dis.* 2018; 24(3).
13. Selinka, H.-C.; Wolde, A.; Sauter, M.; Kandolf, R.; Klingel, K. Virus-receptor interactions of coxsackie B viruses and their putative influence on cardiotropism. *Med. Microbiol. Immunol.* **2004**, *193*, 127–131.
14. Bryant, P.A.; Tingay, D.; Dargaville, P.A.; Starr, M.; Curtis, N. Neonatal coxsackie B virus infection—A treatable disease? *Eur. J. Pediatr.* **2004**, *163*, 223–228.
15. Selinka, H.-C.; Wolde, A.; Sauter, M.; Kandolf, R.; Klingel, K. Virus-receptor interactions of coxsackie B viruses and their putative influence on cardiotropism. *Med. Microbiol. Immunol.* **2004**, *193*, 127–131. [[CrossRef](#)]
16. Wang Y, Zhao H, Ou R, Zhu H, Gan L, Zeng Z, Yuan R, Yu H, Ye M. Epidemiological and clinical characteristics of severe hand-foot-and-mouth disease (HFMD) among children: a 6-year population-based study. *BMC Public Health.* 2020;20(1):801.
17. Gao Y, Wang H, Yi S, Wang D, Ma C, Tan B, Wei Y. Spatial and temporal characteristics of hand-foot-and-mouth disease and their influencing factors in Urumqi, China. *Int J Environ Res Public Health.* 2021;18(9):4919.

18. Jones E, Pillay TD, Liu F, Luo L, Bazo-Alvarez JC, Yuan C, Zhao S, Chen Q, Li Y, Liao Q, Yu H, Rogier van Doorn H, Sabanathan S. Outcomes following severe hand foot and mouth disease: a systematic review and meta-analysis. *Eur J Paediatr Neurol.* 2018;22(5):763–73.
19. Ji H, Fan H, Ai J, Shi C, Bi J, Chen YH, Lu XP, Chen QH, Tian JM, Bao CJ, Zhang XF, Jin Y. Neurocognitive deficits and sequelae following severe hand, foot, and mouth disease from 2009 to 2017, in JiangSu Province, China: a long-term follow-up study. *Int J Infect Dis.* 2022;115:245–55.
20. Tsou YA, Cheng YK, Chung HK, Yeh YC, Lin CD, Tsai MH, Chang JS. Upper aerodigestive tract sequelae in severe enterovirus 71 infection: predictors and outcome. *Int J Pediatr Otorhinolaryngol.* 2008;72(1):41–7.
21. Liang L, Cheng Y, Li Y, Shang Q, Huang J, Ma C, Fang S, Long L, Zhou C, Chen Z, Cui P, Lv N, Lou P, Cui Y, Sabanathan S, van Doorn HR, Luan R, Turtle L, Yu H. Long-term neurodevelopment outcomes of hand, foot and mouth disease inpatients infected with EV-A71 or CV-A16, a retrospective cohort study. *Emerg Microbes Infect.* 2021;10(1):545–54.
22. Dalman C, Allebeck P, Gunnell D, Harrison G, Kristensson K, Lewis G, Lofving S, Rasmussen F, Wicks S, Karlsson H. Infections in the CNS during childhood and the risk of subsequent psychotic illness: a cohort study of more than one million Swedish subjects. *Am J Psychiatry.* 2008; 165(1):59–65.
23. Pedersen EMJ, Kohler-Forsberg O, Nordentoft M, Christensen RHB, Mortensen PB, Petersen L, Benros ME. Infections of the central nervous system as a risk factor for mental disorders and cognitive impairment: a nationwide register-based study. *Brain Behav Immun.* 2020;88:668–74.
24. Zhao MQ, Wang LH, Lian GW, Lin ZF, Li YH, Guo M, Chen Y, Liu XM, Zhu B. Characterization of lymphocyte subsets in peripheral blood cells of children with EV71 infection. *J Microbiol Immunol Infect.* 2020;53(5):705–14.