

## Case Report

### The success rate of Endoflas powder mixed with Curcumin gel as obturating material in Primary Molars: Case- Series.

Ambati Naga Radhakrishna<sup>1</sup>, Alekhya Chowdary Menni<sup>2</sup>, Madu Ghana Shyam Prasad<sup>3</sup>, Shalini ChandraSekhar<sup>4</sup>

<sup>1</sup> Reader, Department of Pedodontics and Preventive Dentistry, India

<sup>2</sup> Post Graduate Student, Department of Pedodontics and Preventive Dentistry

<sup>3</sup> Professor and HOD, Department of Pedodontics and Preventive Dentistry

<sup>4</sup> Senior Lecturer, Department of Pedodontics and Preventive Dentistry

Received 03 March 2017; Accepted 16 April 2017

## ABSTRACT

**Introduction:** Important requisites of an obturating material for primary teeth are that it should resorb at the same rate as the roots of a primary tooth, should be harmless to the periapical tissue and permanent tooth germ, resorb readily if pushed beyond the apex and must be easy to fill and remove as and when necessary. Nowadays herbal products are being recommended for use in dentistry because of their safety, efficacy, cultural acceptability and lesser side effects. Turmeric (Curcumin Longa), is a medicinal herb with bactericidal properties like anti-inflammatory and antimicrobial, thus it can be used as obturating material in primary teeth. **Aims and objectives:** To determine the efficacy of Endoflas powder mixed with Curcumin gel as obturating material in primary teeth. **Materials and Methods:** 4 primary molars indicated for pulpectomy in 4 children (4-9 year-old) were selected. After biomechanical preparation, the four primary molars were obturated with Endoflas powder mixed with Curcumin gel and its efficacy was evaluated both clinically and radiographically at 1 month and 3-month intervals. **Conclusion:** The Endoflas powder mixed with Curcumin gel showed faster resorption of the over pushed material within 1 week, also showed a decrease in inter-radicular radiolucency after 1 month and maintained until 3 month follow-up.

**Keywords:** Pulpectomy, Obturating materials, Curcumin, Endoflas, Antimicrobials, Turmeric.

## INTRODUCTION:

As primary teeth are the best space maintainers, teeth with infected pulps should be retained until exfoliation whenever possible. Although root canal treatment of primary teeth has been advocated for irreversible pulpitis, no consensus exists as to the preferred filling material. The available obturating materials for primary teeth such as zinc oxide eugenol, Endoflas are associated with certain disadvantages like slower resorption of the extruded material which is seen with zinc oxide eugenol and discoloration of the teeth with Endoflas [1].

Curcumin is a phenolic compound that has shown bactericidal properties when tested clinically with a greater medicinal effect such as antioxidant, anti-inflammatory and anti-microbial properties

which may prove to be a boon to dentistry [2]. Endoflas has the advantage of possessing ability to disinfect dentinal tubules and hard-to-reach accessory canals, at the same time it is associated with disadvantage of causing periapical irritation which is due to its liquid component eugenol [3].


Thereby considering the medicinal properties of Curcumin and advantages of Endoflas powder for the additive effect Endoflas powder is mixed with Curcumin gel (ABOTT CURENEXT GEL) to overcome the disadvantage of Endoflas-eugenol mix and used as an obturating material in primary teeth. This case series presents the success rate of Endoflas powder mixed with Curcumin gel as obturating material in pulpectomy treated primary molars.

## Method of preparation of Curcumin Endoflas mix:

A ratio of 1:3 Curcumin gel to Endoflas powder was mixed on a glass slab with stainless steel spatula, by incorporating the Endoflas powder into Curcumin gel in increments, using the folding technique into a thick mix.



(a)



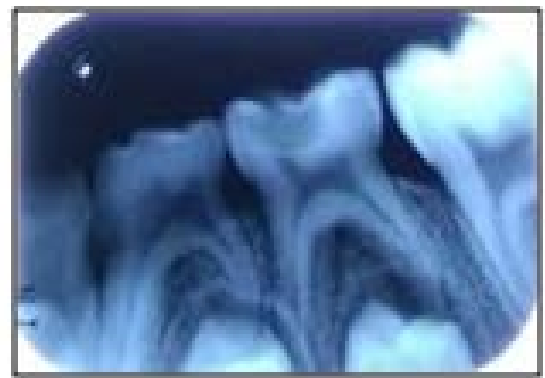(b)

Figure 1: (a,b)

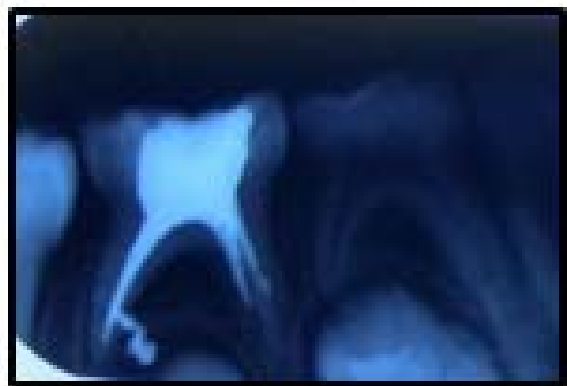
### CASE 1

An 8-year-old male child presented to the Department of Pedodontics and Preventive Dentistry, with a chief complaint of pain in lower left back tooth region. Clinical examination revealed deep dental caries with tenderness on percussion in relation to 75. Based on clinical and radiographic findings (Fig.1a) it was diagnosed as chronic irreversible pulpitis in relation to 75, treatment option considered was pulpectomy. After parental consent, under local anesthesia (concentration of 1:80,000) and rubber dam isolation pulpectomy procedure was carried out. The access to the chamber was obtained after removal of the carious tooth structure using BR40

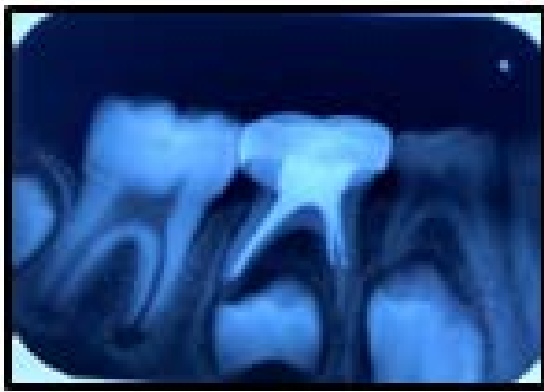
bur. The coronal pulp was removed with a spoon excavator. An intraoral periapical radiograph was taken to confirm the working length. Biomechanical preparation was done with k files 21mm length using step back technique. A2.5% sodium hypochlorite (20ml) irrigating solution was used alternatively with saline. Paper points were used for drying the canals and were obturated with Endoflas powder mixed with Curcumin gel using incremental technique. Later the access cavity was sealed with a thick paste of zinc oxide eugenol, and a radiograph was taken to determine the extent of the filling (Fig.1b). The root canal filling was followed by placement of preformed stainless steel crown after 1 week interval using standard technique and complete resorption of the extruded material was observed at the time of stainless steel crown placement (Fig.1c). At the 3<sup>rd</sup> month (Fig.1d) follow-up the tooth remained asymptomatic.



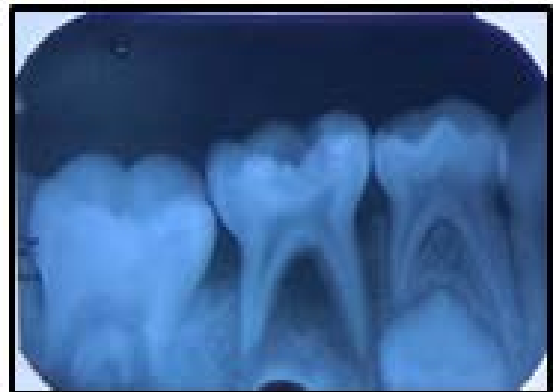1a



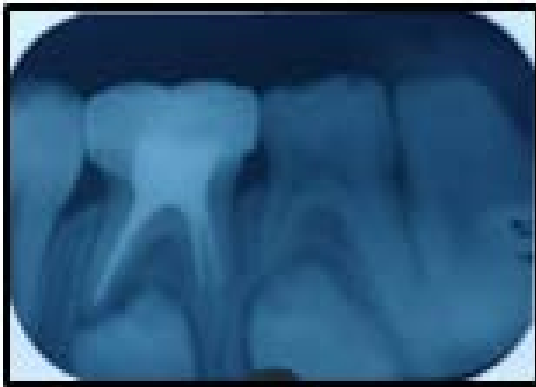1b



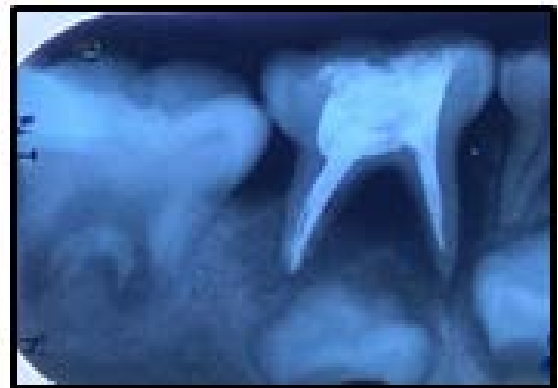1c



2a



1d

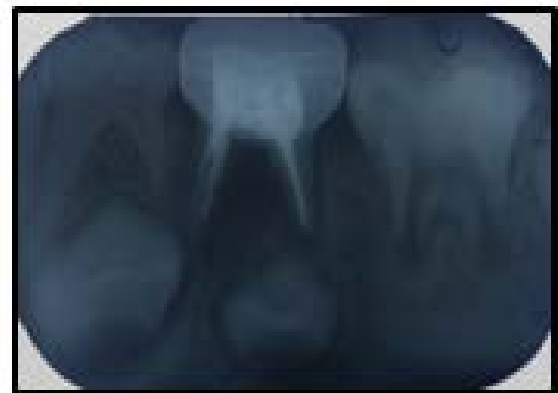

2b

Figure (1a): Preoperative radiograph, Figure (1b): Immediate postoperative radiograph, Figure (1c): post operative radiograph after 1week, Figure (1d): 3month follow up

#### CASE 2

An 8-year-old female is presented to the Department of Pedodontics and Preventive Dentistry, with a chief complaint of pain in the lower right back tooth region. Clinical examination revealed deep dental caries and mobility with 85. Based on clinical and radiographic findings (Fig.2a) the diagnosis was chronic irreversible pulpitis, treatment option considered was pulpectomy (Fig.2b) followed by stainless steel crown. A similar protocol as case 1 was followed for pulpectomy procedure and followed after 3 months. At the third month follow-up, 85 displayed decreased mobility clinically, with decreased inter-radiolucency radiographically (Fig.2c).



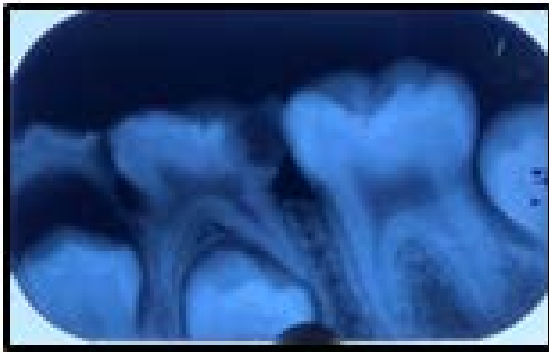2c

Figure (2a): Pre-operative radiograph, Figure (2b): Immediate postoperative radiograph, Figure (2c): 3month follow up.

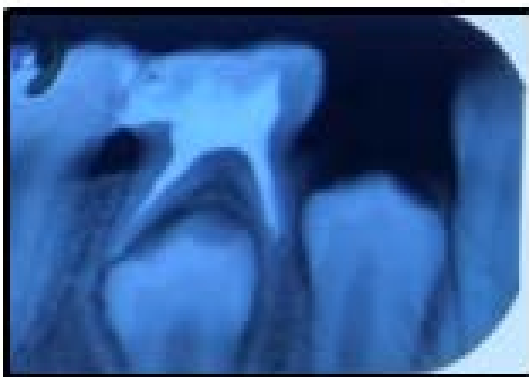#### CASE 3

An 8-year-old girl presented to the Department of Pedodontics and Preventive Dentistry, St. Joseph Dental College, with a chief complaint of pain in the lower left back tooth region of the jaw. Clinical examination revealed cariously involved 84 and 85. Based on clinical and radiographic findings (Fig.3a) the diagnosis was chronic irreversible

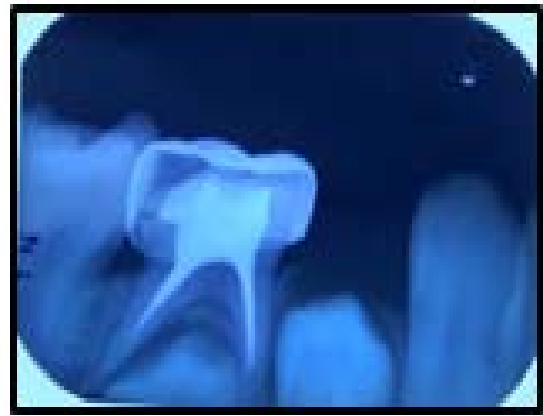pulpitis in relation to 84, 85. The treatment option considered was pulpectomy (Fig.3b) followed by stainless steel crown in relation to 85 and extraction in relation to 84, due to pathological root resorption with associated radiolucency involving underlying tooth bud. Extraction was performed in relation to 84 and pulpectomy was carried out in relation to 85. A similar protocol as case 1 was followed for pulpectomy procedure and was followed up after 1 and 3months. At the 3<sup>rd</sup> month follow-up, there is decreased interradicular radiolucency radio graphically in relation to 85 (Fig.3c) and 1mm space loss was observed in relation to 84. In order to regain the lost space an open coil space regainer was placed in relation to 84 (Fig.3d).



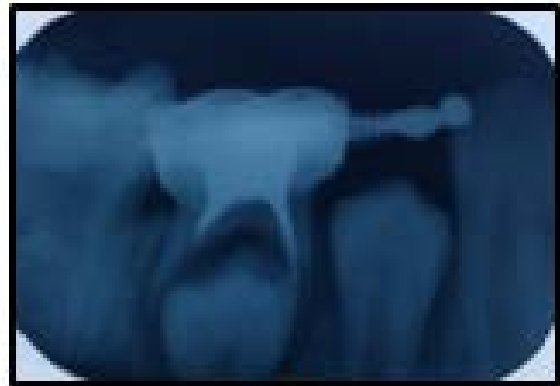3a



3b



3c

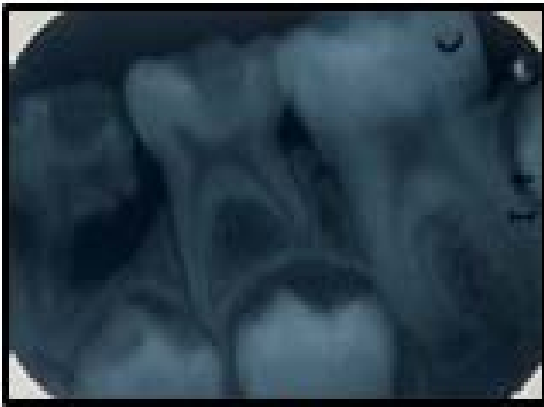

3d

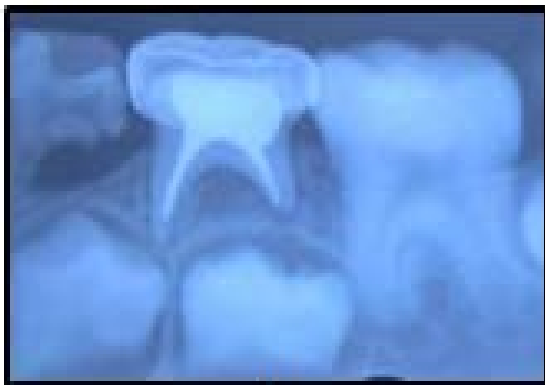Figure (3a): Pre-operative radiograph, Figure (3b): Immediate postoperative radiograph, Figure (3c): 3-month follow-up, Figure (3d): space regainer in relation to 84

#### CASE 4

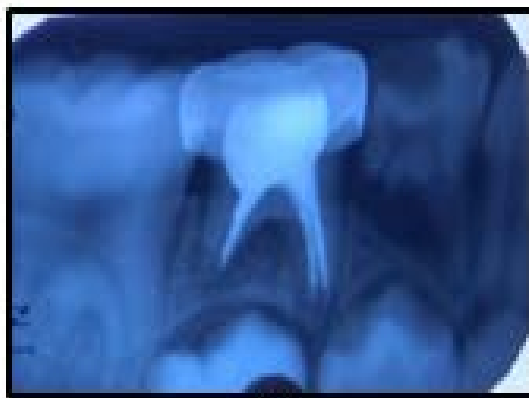
An 8-year-old boy presented to the Department of Pedodontics and preventive dentistry, St. Joseph dental college, with a chief complaint of pain in the lower right tooth back region of the jaw. Based on clinical and radiographic examination the diagnosis was chronic irreversible pulpitis in relation to 84, 85 (Fig.4a). The treatment plan considered was pulpectomy in relation to 85 (Fig.4b) and extraction in relation to 84 followed by lingual arch space maintainer, but extraction was not performed due to the unwillingness of the guardian. The procedure for pulpectomy is followed as described in case 1 and followed up after 3 months (Fig.4c). At the 3<sup>rd</sup> month follow-up visit, the tooth was asymptomatic.



4a



4b



4c

Figure (4a): Pre-operative radiograph in relation to 85, Figure (4b): Immediate post-operative radiograph, Figure (4c): 3 month follow up

## DISCUSSION

The primary goal of pulpectomy is to eliminate infection and retain the tooth in a functional state until it is normally exfoliated. Pulp management of the infected primary teeth involves not only thorough debridement of the root canal system but also obturation by using a material which is

biocompatible and would resorb at the same rate as the roots of the involved tooth, without endangering the succedaneous permanent tooth and its eruption [4]. Calcium hydroxide has been used either as the sole root filling material for primary teeth or in association with iodoform. It is commercially available as Vitapex and Metapex. These products resorb if inadvertently pushed beyond the apex. However, the rate of resorption of the material from within the canals is faster than the rate of physiologic root resorption. Calcium hydroxide has been used either as the sole root filling material for primary teeth or in association with iodoform. It is commercially available as Vitapex and Metapex. These products resorb if inadvertently pushed beyond the apex. However, the rate of resorption of the material from within the canals is faster than the rate of physiologic root resorption.

Calcium hydroxide has been in use either as the sole root filling material for primary teeth or in association with iodoform which is commercially available as Vitapex and Metapex. These products resorb if inadvertently pushed beyond the apex. However, the rate of resorption of the material from within the canals is faster than the rate of physiologic root resorption [5].

Endoflas is a resorbable paste produced in South America and contains components similar to that of Vitapex, with the addition of zinc oxide and eugenol. It also has a drawback of causing tooth discoloration. Praveen et al in their study showed a lower success rate of 58% when there was overfilling but 83% success in cases with flush and under filled root canals. Thus, Endoflas may be successfully used for root canal treatments in primary teeth particularly if care is taken not to overfill [5].

It has been found that the current obturating materials for primary teeth still need to be modified to suit the various clinical situations that are encountered [5]. In search of an obturating



material that can overcome the disadvantages associated with currently used chemicals like calcium hydroxide, antibiotics, non-phenolic biocides, phenolic biocides and iodine compounds, natural herb or traditional plants like curcumin, aloe vera have proved to be a better source and have been utilized as obturating materials in primary teeth [6,4].

Herbs have high antimicrobial, anti-inflammatory, antioxidant (due to the presence of wide variety of active phytochemicals, including flavonoids, terpenoids, lignans, sulfides, polyphenolics, carotenoids, coumarins, saponins, plant sterols, curcumins, phthalides) and biocompatible properties making their use in dentistry more extensive [7]. Among the herbal products, curcumin was able to demonstrate complete eradication of *E. faecalis* in a study conducted by Neelakantan P et al [8]. Another study conducted by A.R. Prabhakar et al showed that there was a gradual decrease in the antibacterial activity of curcumin at 3 and 7 days which may be due to the buffering ability of dentin. Curcumin does not affect the microhardness of root dentin and is a potential intracanal medicament [6].

JayChamele and ChetanBhat conducted an in-vitro study to evaluate the efficacy of turmeric extract as an intracanal medicament in deciduous teeth against *E. faecalis* and found 50% reduction in colony count. They concluded that Curcumin was effective against *E. faecalis* and can be used as intracanal medicament [2]. Kanchi upadhyay et al evaluated the antibacterial efficacy of Curcuma longa (turmeric), calcium hydroxide, calcium hydroxide plus turmeric and metapex against root canal microorganisms and found that turmeric had substantial antibacterial effect as intracanal medicament and also its combination with calcium hydroxide increased its antibacterial efficacy against all the root canal pathogens[9].

Mandrolu and Bhat investigated the anti-bacterial potential of curcumin, against standard strains of common endodontic bacteria. The bacterial strains of *Streptococcus mutans* (ATCC 35668), *Actinomyces viscosus* (ATCC 10048), *Lactobacillus casei* (ATCC 334), *Porphyromonas gingivalis* (ATCC 33277), *Prevotella intermedia* (ATCC 25611), *Enterococcus faecalis* (ATCC 29212) from the stock were revived by plating on blood agar medium and

concluded that curcumin has the potential to be developed into medicament for the treatment of various endodontic diseases [10].

Neelakantan P et al evaluated the antimicrobial efficacy of curcumin against *Enterococcus faecalis* biofilm formed on tooth substrate in vitro. Sodium hypochlorite (NaOCl) and Chlorhexidine (CHX) served as standards for comparison. In the 2-day and 2nd week biofilms, curcumin and NaOCl showed complete inhibition, in 8 week biofilms, samples treated with curcumin showed  $553 \pm 137.6$  CFU/mL, which was significantly higher than NaOCl (0 CFU/mL), but lower than CHX ( $2551 \pm 129.8$ ) and saline control [7].

Hence, the present case series evaluated the clinical success of novel combination of Endoflas powder and Curcumin gel as obturating material and found that this combination exhibited better antimicrobial efficacy as there was decreased inter-radicular radiolucency at follow-up periods and thus it can be suggested as alternative obturating material for primary teeth. The limitations of our case series were small sample size and limited follow-up period.

## CONCLUSION

The Endoflas powder mixed with Curcumin gel obturating material exhibited faster resorption of the over pushed material within 1week follow up, also showed a decrease in inter-radicular radiolucency after 1month and maintained until the 3<sup>rd</sup> month follow-up. However, further clinical studies with more sample size are recommended to draw any conclusions.

## Acknowledgments

We thank Fr.Bala.P, Fr.Nelli George, Dr.Sleeva Raju for their support throughout the study.

## REFERENCES

1. Trairatvorakul C, Chunlasikaiwan S. Success of Pulpectomy With Zinc Oxide-Eugenol Vs Calcium Hydroxide/Iodoform Paste in Primary Molars: A Clinical Study. *Pediatr Dent.* 2008;30:303-308
2. Chamele J, Bhat C. Efficacy of turmeric extract as an intracanal medicament in deciduous teeth against *Enterococcus faecalis*: An in vitro study. *Int.J.Curr.Microbiol.App.Sci.* 2014;3:17-25

3. Rewal N, Thakur AS, Sachdev V, Mahajan N. Comparison of Endoflas and Zinc oxide Eugenol as root canal filling materials in primary dentition. J Indian Soc Pedod Prev Dent. 2014;32:317-21
4. Khairwa A, Bhat M, Sharma R, Satish V, Maganur P, Goyal AK. Clinical and radiographic evaluation of zinc oxide with aloe vera as an obturating material in pulpectomy: An *in vivo* study. J Indian Soc Pedod Prev Dent. 2014;32:33-8
5. P Praveen, A Anantharaj, Karthik Venkataraghavan, PSrathiba Rani, R Sudhir, AR Jaya. A review of obturating materials for primary teeth. Streamdent 2011;1:1-4
6. Prabhakar AR, Swapnil T, Savita H, Sugandhan S. Comparison of Antibacterial Efficacy of Calcium Hydroxide Paste, 2% Chlorhexidine Gel and Turmeric Extract as an Intracanal Medicament and their Effect on Microhardness of Root Dentin: An *in vitro* Study. Int J Clin Pediatr Dent..2013;6:171-177.
7. Kurian B, Swapna D V, Nadig RR, Ranjini M A, Rashmi K, Bolar SR. Efficacy of calcium hydroxide, mushroom, and *Aloe vera* as an intracanal medicament against *Enterococcus faecalis*: An *in vitro* study. Endodontology 2016;28:137-42
8. Neelakantan P, Subbarao C, Sharma S, Subbarao CV, Garcia-Godoy F, Gutmann JL. Effectiveness of curcumin against *Enterococcus faecalis* biofilm. Acta Odontol Scand. 2013;71:1453-7.
9. Upadhyay K, Kencheppa M, Gupta S, Sharma P, Roy S, Gupta P. Comparison of Antibacterial Efficacy of Combination of Turmeric and Calcium Hydroxide with Three Intracanal Medicaments against Various Endodontic Bacteria: An *in vitro* Study. J Orofac Res 2015;5:113-117
10. Praveenkumar. S. Mandroli and KishorBhat. An *in vitro* evaluation of antibacterial activity of curcumin against common endodontic bacteria. J App Pharm Sci, 2013; 3: 106-108