



Short Communication

Protective Effects of *Sida Veronicaefolia* against Paracetamol Induce Hepatotoxicity in Experimental Animals

Vidhi Jain¹, Manmeet Singh Saluja²

¹Research Scholars, Department of Pharmacy, Sunrise University, Alwar, Rajasthan.

²Professor, Department of Pharmacy, Sunrise University, Alwar, Rajasthan.

Article Info: Received 10 August 2022; Accepted 07 September. 2022

DOI: <https://doi.org/10.32553/jbpr.v11i6.929>

Address for Correspondence: Vidhi Jain

Conflict of interest statement: No conflict of interest

Abstract:

In the current research, rats will be given paracetamol (hepatotoxic), and the hydroethanol (HEESV) extract of the leaves of *Sida veronicaefolia* will be tested to see how well it protects the rats' livers from damage caused by the paracetamol. Liver function tests and serum profiles were used to provide an estimate of the hepatoprotective effects of HEESV at a dose of 500 mg/kg. According to the findings, the extracts of the chosen plant not only provide a strong hepatoprotective impact by lowering blood levels of serum transaminases (SGPT and SGOT), alkaline phosphate, and total bilirubin, but they also considerably enhance the levels of total protein. The effects of HEESV were quite similar to those of the standard medication silymarin.

Introduction

The last three decades have seen a rise in the number of studies that provide convincing evidence that herbal medication may help prevent, slow, or even reverse the progression of chronic illnesses. (Mehrola, 1990). Because of its greater cultural acceptance, more compatibility with the human body, and less adverse effects, herbal medicine continues to be the primary form of treatment for around 75–80 percent of the world's population, the majority of which lives in developing nations. Within the last few years, there has been a discernible rise in the use of their services in industrialised nations like as Germany, France, the European Union, and the United States of America.

There are over 45,000 plant species in India, and many thousands of them have been attributed with medicinal characteristics. The

government of India has put in place a legal system to control the quality, safety, effectiveness, and practise of herbal medicine. At the moment, there are over 4,000, 000 ayurvedic practitioners who are registered with the government. The sale of herbal medicine in India as over-the-counter products, ethical and classical formulation, and having remedies from the ayurveda, unani, and siddha systems accounts for approximately one billion dollars of the country's total turnover, while exports bring in an additional eighty million dollars. In spite of the fact that India is a veritable treasure trove of herbal medicine, around eighty percent of the nation's exports to the developed countries are in the form of basic ingredients rather than completed formulations, which

results in a poor income for the country. (Sapna Shrikumar, 2007)

Herbal medicines play an important part in the treatment of a variety of liver disorders, and the majority of these medicines hasten the liver's natural healing process. In India, both traditional and folk medical traditions make use of a large number of different medicinal plants and preparations made from those plants in the treatment of liver problems. The World Health Organization estimates that liver illness claims the lives of around 18,000 individuals annually. The lack of varied liver protective medications is one of the most significant factors contributing to the prevalence of major liver illnesses. Cirrhosis, cholestasis, hepatitis, portal hypertension, hepatic encephalopathy, hepatic failure, and specific cancers like hepatoma are some of the most frequent diseases that affect the liver.

To treat liver problems, there is a wide variety of therapy options available to choose from. Herbal medicine plays an important part in the treatment of a wide variety of liver conditions in allopathic medical procedures. However, since we do not yet have a treatment that is adequate for liver problems, the hunt for medications that are useful in protecting the liver from damage continues.

In India, traditional and tribal medicinal practises make use of a large number of plants that are either unknown or poorly understood. The scientific community does not now understand the therapeutic potential of these plants. This study focuses on the hepatoprotective efficacy of *Sida veronicaefolia* against the liver damage produced by paracetamol in rats.

Since prehistoric times, people have been looking for ways to heal a variety of illnesses using medicines derived from natural sources. This search continues today. In the hunt for the creation of novel and beneficial therapeutic agents, the logical techniques and experience of folk medicine offered a helpful approach.

The primary objective of this study is to identify novel hepatoprotective medications that may be derived from native plants and that are both effective and safe to use. These plants have a long history of use in medical practises. To far, there has been insufficient research conducted on these substances to define their chemical make-up, modes of action, or levels of toxicity.

The primary purpose of this effort is to produce a robust hepatoprotective drug for the therapeutic treatment that has little or no adverse effects.

A straggling wayside plant known as *Sida veronicaefolia*, which belongs to the Malvaceae family, may often be seen growing in shady locations. It is most common to see it growing in areas where the forest has been cleared, as well as in overgrown areas of grass in public parks and gardens (Lutterodt et al., 1988a). There are a number of other names for it, including Rajbala, Bhumibala, Farid buti, and Shaktibala. It is able to eliminate the three doshas (vata, pitta, and kapha) that are found in the body, as well as provide the body vigour and a glowing appearance (Dash et al., 1991).

Because of its widespread use in traditional medicine, the *Sida veronicaefolia* plant is very well-liked by rural women, particularly in the regions where it grows in its natural habitat. This is because the plant is known for its ability to shorten labour and lessen the associated pain during childbirth. It is supposed to make the process of childbirth nearly painless and to shorten the amount of time that women bleed after giving birth. In the latter stages of pregnancy, a soup made from this plant is consumed (Lutterodt et al., 1988b). According to Lutterodt's findings, an abortifacient effect may be produced in pregnant rats by an alcoholic extract of *Sida veronicaefolia*. When taken orally and delivered between the 15th and 17th day of pregnancy, a dosage exerts an abortifacient effect (Lutterodt et al., 1988b). It has also been claimed that the water-soluble fraction of an alcoholic extract of *Sida veronicaefolia* contains an active component

that is analogous to muscarine (Yua *et al.*, 2008). In a similar vein, the anticancer activity of the plant's leaves has also been documented (Saluja *et al.*, 2012). In the plant, several pharmacologically active phytoconstituents such as alkaloids, flavonoids, triterpenoids, phenolic compounds, saponins, amino acids, and protein were found, according to an in-depth ethnobotanical study (Saluja *et al.*, 2012). In light of the fact that no activity of this kind has been documented for any of the plant extracts listed above, the aim of the current investigation was to investigate the hepatoprotective potential of a number of different plant extracts.

Method and Materials

Procurement and Authentication of the Plant

The leaves of *Sida veronicaefolia* were gathered from the surrounding region of Kota, Rajasthan, and then sent to Kota University, Kota, Rajasthan, where they were certified by Dr. S. K. Billore. In order to facilitate investigations, the voucher specimen (KCP/PHCOG/VS-1) was submitted to the Department of Pharmacognosy at Kota College of Pharmacy.

Preparation of extracts of *Sida veronicaefolia*

In a Soxhlet apparatus, 500g of powdered leaves were extracted with hydroethanol. The materials were concentrated by evaporation (Farnsworth *et al.*, 1966).

Animals

Wistar albino rats (150-200 g) was procured from Central Drug Research Institute, Lucknow, India. The animals were fed with standard pellet diet (Hindustan lever Ltd. Bangalore) and water *ad libitum*. All the animals were acclimatized for a week before use. The experimental protocols were approved by Institutional Animal ethics Committee after scrutinization. Animals were received the drug by oral gavages tube. All the animals were care of under ethical consideration as per the

CPCSEA guidelines (CPCSEA, 2003) with regular inspections of rats. The laboratory conditions duly undertaken by registered veterinary practitioner.

Chemicals

All the chemicals and solvents were of analytical grade. Silymarin was obtained as gift sample from Micro Lbs, Goa, India. Standard kits for SGOT, SGPT and ALP etc. were obtained from Span Diagnostics Ltd., India.

Evaluation of hepatoprotective activity by paracetamol induced hepatotoxicity in rats

Rats were divided into 5 groups of 6 animals (n=6) in each (Kapoor *et al.*, 1994).

Group I: Received water (5 ml/kg. p.o) for 9 days once daily, and served as normal control.

Group II: Received water (5 ml/kg. p.o) for 9 days once daily and paracetamol (1 g/kg, p.o.) on the 7th day.

Group III: Received standard drug silymarin (25 mg/kg. p.o.) for 9 days once daily and paracetamol (1 g/kg, p.o.) on the 7th day.

Group IV: Received *HEESV* (500 mg/kg) 9 days once daily and paracetamol (1 g/kg, p.o.) on the 7th day.

Assessment of hepatoprotective activity

On 10th day, blood was obtained from animals by puncturing retro orbital plexus. Blood samples were allowed to clot for 45 min at room temperature. Serum was separated by centrifugation at 2500 rpm at 30°C for 15 min and utilized for the estimation of various biochemical parameters including SGOT & SGPT (Reitman *et al.*, 1957), ALP (Kind *et al.*, 1954), serum bilirubin (Amour *et al.*, 1965) and serum protein (Lowry *et al.*, 1951) After collection of blood samples, the animals were sacrificed under deep ether anesthesia.

Morphological parameters like weight of animals, weight of liver have also been used to evaluate the protective effect of the drug. Hepatoprotective chemical causes loss in liver

weight/100 gm body weight of rats (Avadhoot *et al.*, 1991; Bhanwra *et al.*, 2000).

Histopathology studies

A portion of liver tissue of all the animal groups was excised and then washed with normal saline. The liver tissues were fixed in 10% buffered neutral formalin for 48h and then with bovine solution for 6 h and were then processed for paraffin embedding. By using a microtome, sections of 5 mm thickness were taken and stained with hematoxylin and eosin. These sections were examined under light microscope using a magnification of 100X (Mankani *et al.*, 2005).

Statistical Significance

The results of the study were expressed as mean \pm SEM, n=6. ANOVA (Gennaro *et al.*, 1995) was used to analyze and compare the data, followed by Dunnet's (Dunnet *et al.*, 1964) test for multiple comparisons.

Results

Acute toxicity study

There was no mortality found amongst the graded dose groups of animals and they did not show any toxicity or behavioral changes at a dose level of 5000 mg/kg. This finding suggests that the *HEESV* was safe or non-toxic to rats and hence doses of 500 mg/kg, p.o. were selected for the study.

Effect of *HEESV* on serum marker enzyme levels

There was a significant elevation in the levels of serum marker enzymes like SGOT, SGPT and ALP content of Paracetamol intoxicated animals. In contrast, pretreatment with *HEESV* (500 mg/kg, po) and silymarin (25 mg/kg, po) exhibited an ability to counteract the hepatotoxicity by decreasing serum marker enzymes. The results were showed in table no 1.

Effect of *HEESV* on biochemical parameters

In paracetamol treated groups, there was a significant increase in total bilirubin and significant reduction in total protein content. Whereas, pretreatment with *HEESV* (500 mg/kg, po) caused significant reduction in total bilirubin and significant increase in total protein. The results were showed in table no.1.

Effect of *HEESV* on liver weight

Paracetamol intoxicated group of animals, weight of the liver was significantly increased, but it was normalized in *HEESV* (500 mg/kg, po) treated groups of animals. A significant reduction in liver supports this finding. The results were showed in table no.2.

Histopathology

Histopathological studies of liver also provided a supportive evidence for biochemical analysis. Histological changes such as steatosis (fatty changes in hepatocytes) and perivenular fibrosis were observed in paracetamol treated (toxic) control group. Both the plant extracts has prevented these histological changes. The results were showed in fig. no. 1.

Table No. 1: Effect of *HEESV* extracts on serum enzyme and biochemical parameter in Paracetamol induced hepatotoxicity in rats.

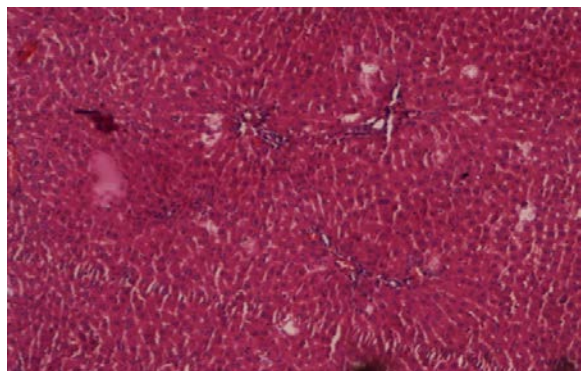
Treatment/ Dose	SGPT U/L	SGOT U/L	ALP U/L	Total Bilirubin mg/dl	Total Protein gm/dl
Normal	62.0 \pm 3.71	168.04 \pm 2.80	190.0 \pm 8.01	0.38 \pm 0.06	9.57 \pm 0.24
Induced (Paracetamol)	154.8 \pm 8.64*	248.4 \pm 9.24*	360.20 \pm 8.82*	5.42 \pm 8.11*	5.42 \pm 8.46*
Silymarin 25mg/kg	86.86 \pm 8.63**	176.16 \pm 8.17**	166.35 \pm 4.27**	0.45 \pm 0.82**	9.21 \pm 4.26**
SVAQE (500mg/kg)	120.21 \pm 4.76***	198.0 \pm 9.46***	200.22 \pm 8.66***	0.62.0 \pm 0.58***	8.18 \pm 1.48***

Values are mean \pm SEM, n= 6. (One way ANOVA Followed by Dunnette multiple Comparisons test). Statistically significance of ** P<0.01, *** P<0.001, when compared with respective control.

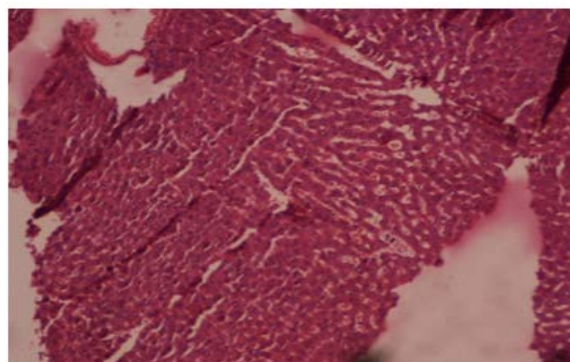
Table No. 2: Effect of HEESV extract on liver weight in Paracetamol induced hepatotoxicity in rats.

Treatment/ Dose	Liver weight (wt/100gm bw)
Normal	6.84 \pm 0.06
Induced (Paracetamol)	8.84 \pm 0.48*
silymarin 25mg/kg	7.02 \pm 0.46***
HEESV (500mg/kg)	7.64 \pm 0.86***

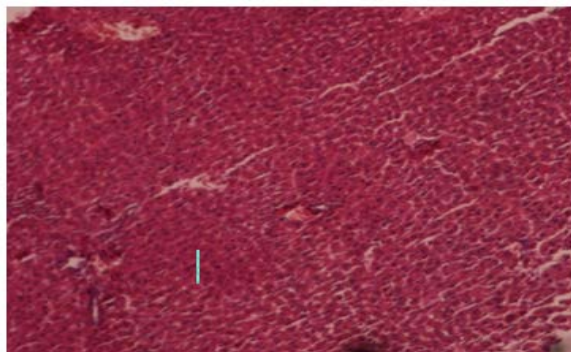
Values are mean \pm SEM, n= 6. (One way ANOVA Followed by Dunnette multiple Comparisons test). Statistically significance of ** P<0.01, *** P<0.001, when compared with respective control.



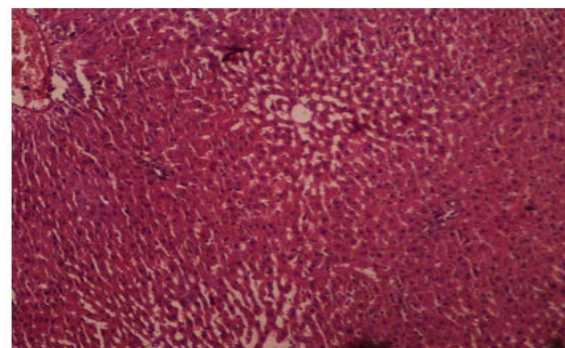
Normal control



Positive control



Standard Silymarin



Heesv Ext.

Discussion

There are many factors which are responsible for the liver damage or injuries such as chemicals and drugs. In the present study paracetamol was used to induce hepatotoxicity, since it is clinically relevant. Paracetamol produces a constellation of dose related deleterious effects in the liver (Leo et al., 1982). The majority of paracetamol is metabolized in the liver and individuals who abuse alcohol by routinely drinking 50-60 g

(about 4 to 5 drinks) of ethanol per day are at risk for developing alcoholic liver disease (Zakhari et al., 2007). In addition, both acute and chronic ethanol administration cause enhanced formation of cytokines, especially TNF-alpha by hepatic Kupffer cells, which have a significant role in liver injury (Zhou et al., 2003; Thurman et al., 1998; Tsukamoto et al., 2001). Besides the development of fatty liver (steatosis), another early sign of excessive ethanol consumption is liver enlargement and protein accumulation, both of which are

common findings in alcoholics and heavy drinkers (Baraona et al., 1975; Baraona et al., 1977).

Elevated levels of serum glutamic oxaloacetic transaminase (SGOT) and serum glutamic

pyruvic transaminase (SGPT) are indications of hepatocellular injury (Yue et al., 2006). In the present study *HEESV* at a dose of 500 mg/kg, po caused a significant inhibition in the levels of SGOT and SGPT towards the respective normal range and this is an indication of stabilization of plasma membrane as well as repair of hepatic tissue damage caused by paracetamol. On the other hand suppression of elevated ALP activities with concurrent depletion of raised bilirubin level and an increase in the total plasma protein content suggests the stability of biliary dysfunction in rat liver during hepatic injuries with toxicants (Mukherjee et al., 2002).

These results indicate that *HEESV* preserved the structural integrity of the hepatocellular membrane and liver cell architecture damaged by paracetamol which was confirmed by histopathological examination.

Phytochemical screening revealed that *HEESV* contains active pharmacological constituents such as flavonoids, alkaloids, phytosterols and phenolic compounds (Saluja et al., 2011) However, it has been already reported that such phytoconstituents like phenolic compounds, flavonoids, tannins (Paya et al., 1993) are known to possess hepatoprotective activity in various experimental models. Therefore it has been suggest that the hepatoprotective activity shown by the *HEESV* can be because of these active phytoconstituents present in the plant which is being also confirmed by the biochemical and histological parameters. The plant selected for the present study has demands for further phytochemical as well as pharmacological research such isolation of principle active phytoconstituents, evaluation of various pharmacological activities. Out of these aspects some respective parameters are already in process at our organisation.

References

1. Amour FF D', Blood FR, Belden DA. (1965) The manual for laboratory work in Mammalian Physiology. The University of Chicago Press, Chicago, 126-128.
2. Anandan R, Deepa Rekha R, Devaki T. (1999) Protective effect of *Picrorrhiza kurroa* on mitochondrial glutathione antioxidant system in D-galactosamine-induced hepatitis in rats. Current Science 76: 1543-5.
3. Avadhoot V, Rana V. (1991) Hepatoprotective effect of *Vitex negundo* against carbon tetrachloride-induced liver damage. Arch Pharmacy Research 14(1): 96-98.
4. Baraona E, Leo MA, Borowsky SA, Lieber CS. (1975) Alcoholic hepatomegaly: accumulation of protein in the liver. Science 190: 794-795.
5. Baraona E, Leo MA, Borowsky SA, Lieber CS. (1977) Pathogenesis of alcohol-induced accumulation of protein in the liver. Journal of Clinical Investment 60: 546-554.
6. Bhanwra V, Singh V, Khosla V. (2000) Effect of *Azadirachta indica* (Neem) leaf aqueous extract on paracetamol-induced liver damage in rats. Indian Journal of Physiology and Pharmacology 44(1): 64-68.
7. Chatterjee TK. (2000) Medicinal Plants with Hepatoprotective Properties. Herbal Options. Books and Applied Allied (P) Ltd., Calcutta, 143.
8. CPCSEA. (2003) Indian Journal pharmacology 35: 257-274.
9. Dunnet CW. (1964) New Tables for Multiple Comparisons with a Control. Biometrics 20: 482-491.
10. Farnsworth NR. (1966) Biological and phytochemical screening of plants, Journal Pharmaceutical Science 55: 225-76.
11. Firdoos I, Bhat AR, Azam A. (2009) Antiamoebic coumarins from the root bark of *Adina cordifolia* and their new thiosemicarbazone derivatives. European

- Journal of Medicinal Chemistry, 44(5): 2252-2259.
12. Gennaro AR. (1995) Remington: The science and practice of pharmacy, vol. I, 19th ed, Mack Publishing Company, Easton (PA), pp.111.
 13. Jain AP, Pawar RS, Singhai A. (2006) Anti-inflammatory and anti-nociceptive activity of *Adina cordifolia* bark. Nigerian Journal of Natural Products and Medicines 10: 90-93.
 14. Kapoor V, Pillai K, Hussian SZ, Balani DK. (1994) Hepatoprotective activity of "jigrine" on liver damage caused by alcohol, Carbontetrachloride and paracetamol in rats. Indian Journal of Pharmacology 26: 35-40.
 15. Karan M, Vasisht K, Handa SS. (1999) Antihepatotoxic activity of *Swertia chirata* on carbon tetrachloride induced hepatotoxicity in rats. Phytotherapy Research 13: 24-30.
 16. Kasinadhuni VRR, Rajashekhar G, Rajagopalan R, Sharma VM, Vamsi Krishna C, Sairam P, Sai Prasad G, Sadhukhan S, Gangadhar Rao G. (1999) Antiulcer potential of *Haldina cordifolia*. Fitoterapia 70(1): 93-95.
 17. Kind PRN, King EJ. (1954) Estimation of plasma phosphatase by determination of hydrolysed phenol with amino-antipyrine. Journal Clinical Pathology 7(4): 322-326.
 18. Leo MA, Arai M. (1982) Hepatotoxicity of vitamin A and ethanol in the rat. Gastroenterology 82: 194-205.
 19. Lowry OH, Rosebrough NJ, Farr AL, Randall RJ. (1951) Protein measurement with the Folin phenol reagent. Journal of Biological Chemistry 193: 265-275.
 20. Mankani KL, Krishna V, Manjunatha BK, Vidya SM, Singh SJ, Manohara YN, Raheman A, Avinash KR. (2005) A review of natural products with hepatoprotective Activity. Indian Journal of Pharmacology 37(3): 165-168.
 21. Mukherjee PK. (2002) Quality control of herbal drugs, 1st ed, Business Horizons Pharmaceutical Publication, New Delhi, pp. 531.
 22. OECD. (1996) Guidelines for the testing of chemicals, Test no.423, Acute Oral Toxicity -Acute Toxic Class Method.
 23. Paya M, Ferrandiz ML, Sanz MJ, Alcaraz MJ. (1993) Effects of phenolic compounds on bromobenzene-mediated hepatotoxicity in mice. Xenobiotica 23: 327.
 24. Rajesh MG, Latha MS. (2001) Hepatoprotection by *Elephantopus scaber* Linn in CCl₄- induced liver injury. Indian Journal of Physiology and Pharmacology 45: 481-6.
 25. Reitman S, Frankel S. (1957) A colorimetric method for the determination of serum glutamic oxalacetic and glutamic pyruvic transaminases. American Journal Clinical Pathology 28: 56-63.
 26. Rubinstein D. (1962) Epinephrine release and liver glycogen levels after carbon tetrachloride administration. American Journal of Physiology 203: 1033-1037.
 27. Sabir M, Razdan MK. (1970) Antifertility study with leaf extracts of *Adina cordifolia*. Indian Journal of Physiology and Pharmacology 14(3): 209-210.
 28. Sharma A, Chakraborti KK, Handa SS. (1991) Anti-hepatotoxic activity of some Indian herbal formulations as compared to silymarin. Fitoterapia 62: 229-235.
 29. Subramonium A, Pushpangadan P. (1999) Development of Phytomedicines for liver diseases. Indian J. Pharmacol 31: 166-175.
 30. Suja SR, Latha PG, Pushpangadan P, Rajasekharan S. (2002) Aphrodisiac property of *Helminthostachys zeylanica* in mice. Journal of Tropical Medicinal Plants 3: 191-195.
 31. Thurman RG. (1998) Alcoholic liver injury involves activation of Kupffer cells by endotoxin. American Journal of Physiology 275: 605-611.
 32. Tsukamoto H, Takei Y, McClain CJ, Shimizu H, Sato N, Thurman R. (2001)

- How is the liver primed or sensitized for alcoholic liver disease. *Alcohol Clinical Express Research* 25: 171-181.
33. Ward FM and Daly MJ. (1999) "Hepatic Disease. In: *Clinical Pharmacy and Therapeutics* (Walker R.and C.Edwards Eds.)". Churchill Livingstone, New York. pp. 195-212.
 34. Yoganarasimhan SN. (1996) *Medicinal plant of India.vol-1 Karnataka*. Interline publishing pvt.ltd, Bangalore, pp 232.
 35. Yue M, Yu CH, Ren K, Chen W, Li Y. (2006) Transient elevation of hepatic enzymes in volunteers after intake of alcohol. *Hepatobiliary and Pancreatic Diseases International* 5(1): 52-55.
 36. Zakhari S, Li TK. (2007) Determinants of alcohol use and abuse: Impact of quantity and frequency patterns on liver disease. *Hepatology* 46: 2032-2039.
 37. Zhou Z, Wang L, Song Z, Lambert JC, McClain CJ, Kang YJ. (2003) A critical involvement of oxidative stress in acute alcohol-induced hepatic TNF-alpha production. *American Journal of Pathology* 163: 1137-1146.