



Role of Ultrasonography in the Early Diagnosis of Acute Appendicitis

Amit Kumar Himmatbhai Kabariya¹, Ziaur Rahman²

¹Assistant Professor, Department of Radio-Diagnosis, ICARE Institute of Medical Sciences and Research & Dr. Bidhan Chandra Roy Hospital, Haldia, West Bengal, India

²Assistant Professor, Department of Radio-Diagnosis, ICARE Institute of Medical Sciences and Research & Dr. Bidhan Chandra Roy Hospital, Haldia, West Bengal, India

Article Info: Received 9 May 2019; Accepted 20 June 2019

Corresponding author: Dr. Ziaur Rahman

Conflict of interest statement: No conflict of interest

Abstract:

Background: Acute appendicitis is among the most frequent surgical emergencies that are manifested by the acute abdominal pain and that need to be diagnosed as soon as possible to avoid the development of such complications as perforation and peritonitis. Clinical diagnosis is also difficult because of variable presentation, so it is necessary to use imaging techniques to detect the condition early and accurately, such as ultrasonography.

Aim: To evaluate the role of ultrasonography in the early diagnosis of acute appendicitis and to assess its diagnostic accuracy in correlation with clinical findings.

Methodology: The study was a prospective observational study carried out at the Department of Radio-Diagnosis, ICARE Institute of Medical Sciences and Research and Dr. Bidhan Chandra Roy Hospital, Haldia, West Bengal, India, a period of one year. One hundred and fifty patients having acute appendicitis clinically suspected were included. The information on the demographic features, the clinical presentation, and the ultrasonographic results were gathered and examined. Sensitivity, specificity, positive predictive value (PPV), negative predictive value (NPV) and general accuracy were considered to evaluate the diagnostic performance of ultrasonography.

Results: The majority of patients were in the 10–20 years age group (26.7%), followed by 31–40 years (23.3%). The most frequent symptom of presentation was right iliac fossa pain (100%), then nausea/vomiting (73.3%) and fever (63.3%). In 82% of cases, ultrasonography showed the non-compressibility of the appendix, and in 80% of patients it was seen that the appendiceal diameter exceeded 6 mm. Appendicolith (26.7%), periappendiceal fluid (20%), and the development of an abscess (10%), were also present. Ultrasonography had a sensitivity of 91.3, specificity of 88.2, PPV of 93.1, NPV of 85.0, and the overall diagnostic accuracy of 90%.

Conclusion: Ultrasonography is a very effective, noninvasive, and dependable diagnostic method that can be used to detect acute appendicitis at an early stage. Its sensitivity and accuracy are so high that it is a perfect initial imaging modality especially in resource-constrained facilities and can help in minimizing diagnostic delays and unwarranted surgery.

Keywords: Acute appendicitis, Ultrasonography, Diagnostic accuracy, Sensitivity, Specificity, Imaging.

Introduction:

Acute appendicitis is among the most frequent causes of acute abdominal pain that necessitates emergency surgery and is also a major

healthcare burden in all healthcare systems across the globe [1]. It is inflammation of the vermiform appendix which is normally caused

by luminal obstruction by lymphoid hyperplasia, fecaliths or less frequently by tumor and infection. Perforation, abscess formation and generalized peritonitis are some of the complications that may occur suddenly to the condition unless it is diagnosed and treated. Although medical science has improved, it is still a clinical problem because early acute appendicitis is difficult to diagnose as it has a diverse manifestation and is similar to other diseases of the abdominal cavity [2].

Historically, acute appendicitis diagnosis has been based on clinical assessment, which involves patient history, physical examination and laboratory tests [3]. Classical symptoms of right iliac fossa pain, nausea, vomiting, and fever are normally used to direct the diagnosis, although they are not always present or may resemble other diseases like mesenteric lymphadenitis, urinary tract infections or gynecological disorders. Such diagnostic ambiguity may result in the delays in treatment or even unnecessary surgical procedures, such as negative appendectomies that come with their share of risks and complications [4].

Over the recent years, imaging modalities have been becoming a more significant factor in enhancing diagnostic accuracy [5]. Of these, ultrasonography (USG) has become an important, non-invasive, and easily available tool to evaluate suspected acute appendicitis. Ultrasonography has a number of strengths, such as the lack of ionizing radiation, low cost, portability, and the ability to provide real-time images. It is specifically helpful with vulnerable groups like children and pregnant women where radiation dose effects of computed tomography (CT) are a significant issue. The application of graded compression technique also increases the visualization of the appendix and distinguishes it among bowel loops [6].

Ultrasonography has been established as having a good diagnostic criterion of acute appendicitis [7]. The common sonographic observations are non-compressible, blind-ended tubular structure at the right iliac fossa whose outer diameter is larger than 6 mm, wall thickening, appendicolith, periappendiceal fluid collection

and inflamed surrounding fat which makes it more echogenic. These characteristics not only facilitate the confirmation of the diagnosis, but also assist in detecting complications like perforation and formation of abscess [8]. Nonetheless, factors, including operator competence, patient body habitus, and bowel gas interference could affect the accuracy of ultrasonography.

According to epidemiological research, acute appendicitis is the highest in adolescents and young adults, with the highest rates in the second and third decades of life [9]. It concerns both sexes but male dominance has been slightly reported in some. Appendicitis is one of the most common causes of emergency abdominal surgery worldwide, and thus, it is a major contributor to hospitalization and health care spending. Early and correct diagnosis is thus crucial to minimize morbidity and mortality as well as to maximize the use of resources [10].

Delays in the diagnosis of acute appendicitis or missed diagnosis can be serious [11]. The rates of perforation rise to high levels over time, causing such complications as peritonitis, sepsis, and extended hospitalization [12]. Conversely, over diagnosis could lead to unnecessary surgery and this would expose patients to risks that they could have avoided and adds more costs to healthcare. Thus, the best diagnostic modality is one that is accurate, safe, fast and economical.

Ultrasonography is in this case a valuable first line imaging modality especially in resource constrained environments where they may not access more demanding imaging modalities. It offers good diagnostic data and could help to make clinical decisions and decrease the number of negative appendectomies. Moreover, it is a tool that can be used in assessing acute abdominal pain, as it has the capability of identifying other possible diagnoses [13].

This study seeks to determine the usefulness of ultrasonography in the early detection of acute appendicitis by evaluating its diagnostic quality, image, association with clinical and surgical outcomes [14]. This study aims at contributing to evidence-based practices, which improve the

effectiveness of ultrasonography in the tertiary care setting to enhance early diagnosis, improve patient outcome, and reduce complications related to late intervention [15].

Methodology

Study Design

The Research was a prospective observational evaluation that tried to assess the importance of ultrasonography in early diagnosing acute appendicitis. The aim of the study was to evaluate the diagnostic accuracy, clinical correlation and imaging features of patients presenting with suspected acute appendicitis. The prospective method was chosen to enable real-time assessment of patients which would enable proper clinical examination, imaging result and comparison with intraoperative and histopathological results.

Study Area

The research was carried out in the Department of Radio-Diagnosis, ICARE Institute of Medical Sciences and Research and Dr. Bidhan Chandra Roy Hospital, Haldia, West Bengal, India.

Study Duration

The research was carried out in a duration of one year.

Study Participants

Inclusion Criteria

- Patients who display clinical features that are suggestive of acute appendicitis (e.g., right iliac fossa pain, nausea, vomiting, fever).
- Patients between 10-60 years old
- Patients who received ultrasonographic service at the study center.
- Patients with informed consent to participate.

Exclusion Criteria

- Patients who have undergone appendectomy.
- Pregnant women whose ultrasonographic results were inconclusive.
- Patients who have other diagnosed abdominal pathologies.

- Patients whose clinical or imaging records are not complete.

Sample Size

The study involved 150 patients who met the inclusion criteria. The sample size was based on the fact that it should be sufficient to represent various ages and clinical manifestations of acute appendicitis.

Procedure

Clinical examination and ultrasonographic assessment of all eligible patients were performed with a high-frequency (linear) transducer. An examination was conducted using graded compression technique to see the appendix and the structures that were around it.

Parameters measured in ultrasonography were:

- The existence of a non-compressible tube structure.
- Appendix size more than 6 mm.
- Wall thickening
- Presence of appendicolith
- Periappendiceal fluid collection
- Abscess formation

A structured proforma was used to ensure consistency in recording findings. All patients were then treated based on clinical signs and ultrasonographic results were compared with intraoperative results and histopathological analysis where surgery was done. Patient data were kept confidential and ethical approval was gained with the Institutional Ethics Committee of the hospital.

Statistical Analysis

The data gathered was put in SPSS version 27.0 (IBM, USA) to analyze them statistically. The data were summarized using descriptive statistics like mean, standard deviation, frequency, and percentage. Ultrasonography performance was tested on the basis of diagnostic performance, i.e., calculating sensitivity, specificity, positive predictive value (PPV), negative predictive value (NPV), and the overall accuracy. Chi-square tests were used to test the associations between clinical findings

and ultrasonographic results. A p-value less than 0.05 was taken to be significant.

Result

The demographic dispersion of the 150 patients that were used in the study is depicted in Table 1 according to their age groups. The age group of 10-20 years had the highest percentage of patients, with 40 cases (26.7%), which shows that over a quarter of the research population is

in this age group. This was followed by the 31–40 years age group with 35 patients (23.3%), and the 21–30 years group with 30 patients (20%). The highest number of patients (25) was in the age group of 41-50 years (16.7%), and the lowest number of patients (20) was in the age group of above 50 years. The distribution is graphically illustrated in Figure 1, which shows a greater concentration of cases within the younger age groups and a decreasing frequency with increasing age.

Table 1: Demographic Distribution of Patients

Age Group (years)	Frequency	Percentage (%)
10–20	40	26.7
21–30	30	20
31–40	35	23.3
41–50	25	16.7
>50	20	13.3

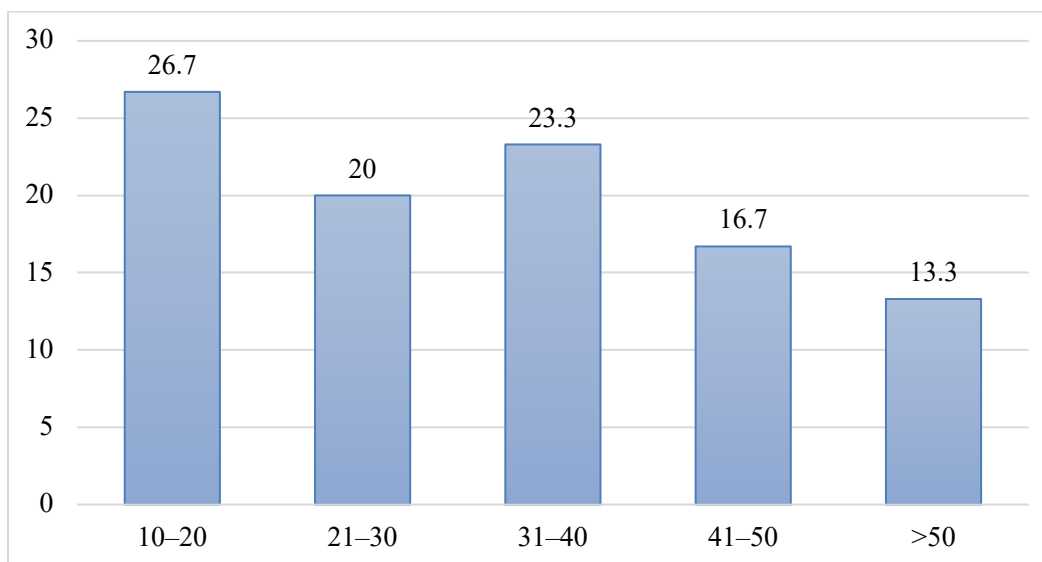


Figure 1: Visual Representation of Demographic Distribution of Patients

The age distribution observed indicates that acute appendicitis is more of a disease that affects the younger population especially those in the first three decades of their lives. The highest incidence between the ages 10-20 years might be explained by the fact that during adolescence, the lymphoid tissue activity in the appendix is likely to be high and therefore may predispose the luminal obstruction, which is a contributing factor to the pathogenesis of appendicitis. Moreover, dietary habits and

lifestyles among the younger generations could also be the factors contributing to this trend. The fact that the percentage of cases in the age groups 21-40 was relatively high also contributes to the idea that acute appendicitis is a relatively frequent disease among young and middle-aged adults. On the whole, this tendency is consistent with the known clinical data and emphasizes the need to keep the index of suspicion high and use early diagnostic tools like ultrasonography, particularly in young patients

with abdominal pain to implement appropriate intervention in time and minimize the risk of complications.

Table 2 shows the clinical features of the 150 patients that were used in the study. The most consistent symptom was right iliac fossa pain, which was present in all patients (150 cases, 100%), and thus it is the primary presenting complaint. Gastrointestinal disturbance was highly correlated (nausea and/or vomiting were

seen in 110 patients (73.3%). In 95 patients, there was fever (63.3%), indicating the presence of an inflammatory or infectious process. Loss of appetite was noted in 85 patients (56.7%), which is a common but relatively less common symptom. These findings are graphically demonstrated in figure 2 with the right iliac fossa pain being the most prevalent followed by nausea/vomiting, fever, and loss of appetite in that order of frequency.

Table 2: Clinical Presentation

Symptom	Frequency	Percentage (%)
Right iliac fossa pain	150	100
Nausea/Vomiting	110	73.3
Fever	95	63.3
Loss of appetite	85	56.7

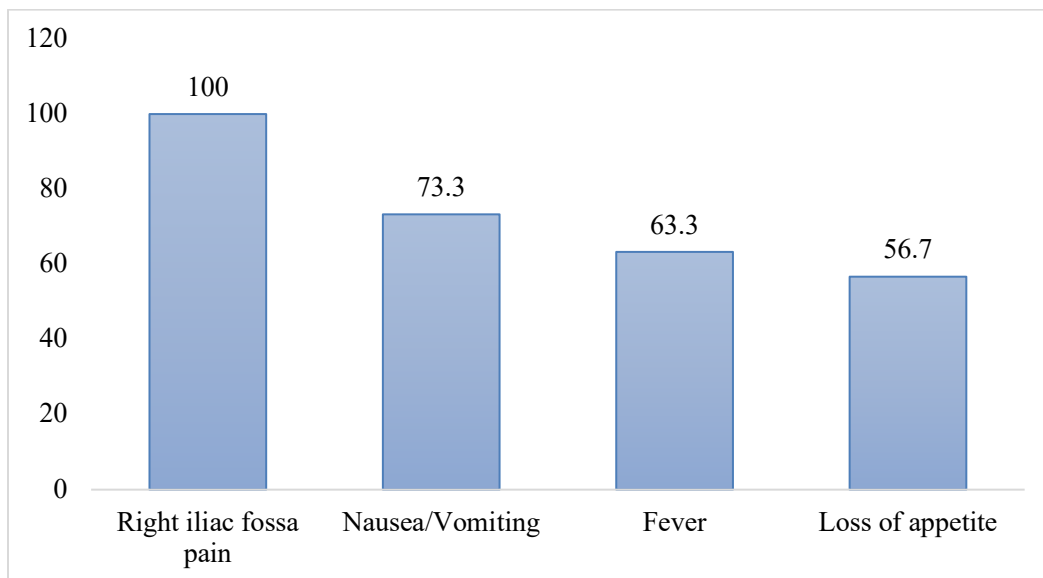


Figure 2: Visual Representation of Clinical Presentation

The data of the clinical presentation demonstrates that the right iliac fossa pain is the most characteristic symptom of acute appendicitis and is the most dependable clinical sign to suspect it first. The classical clinical presentation of appendicitis, characterized by gastrointestinal upsets and systemic inflammatory response is supported by the high prevalence of related symptoms like nausea, vomiting, and fever. The fact that fever occurs in a substantial number of patients is indicative of inflammatory progression, whereas anorexia is indicative of early systemic effects. The

difference in frequency of these attendant symptoms however, means that a patient may not always present with the full classical triad which at times may complicate clinical diagnosis.

Table 3 summarises the ultrasonographic results found in the 150 patients referred to acute appendicitis. In 123 patients (82%), the most frequent result was a non-compressible appendix, which is one of the main sonographic manifestations of inflammation. This was immediately succeeded by a greater appendiceal

diameter more than 6 mm in 120 patients (80%), another significant diagnostic criterion. Appendicolith was identified in 40 individuals (26.7%), which implied that there was luminal obstruction in the cases. The collection of

periappendiceal fluid was seen in 30 patients (20%), which indicates local inflammatory changes or early complication. In 15 patients (10%), abscess formation, a sign of complicated or more severe appendicitis, was observed.

Table 3: Ultrasonographic Findings

Finding	Frequency	Percentage (%)
Non-compressible appendix	123	82
Diameter >6 mm	120	80
Appendicolith	40	26.7
Periappendiceal fluid	30	20
Abscess formation	15	10

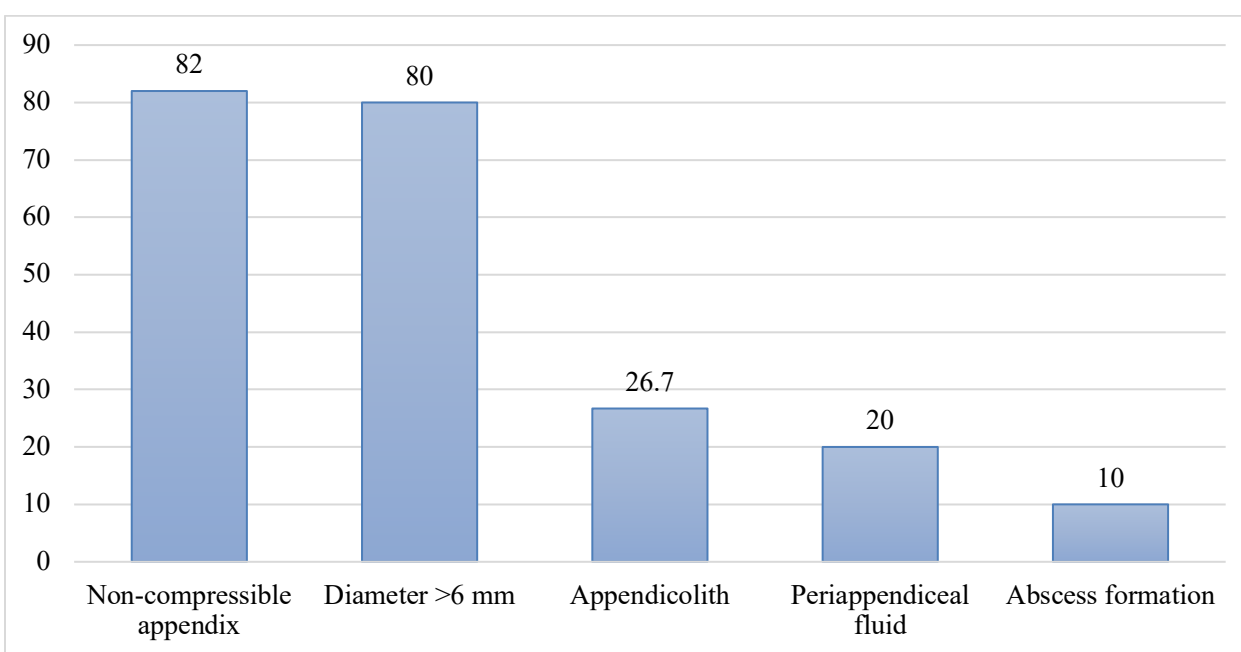


Figure 3: Visual Representation of Ultrasonographic Findings

The ultrasonographic results highlight the great diagnostic power of the main primary indicators, especially the non-compressible appendix and the appendiceal diameter exceeding 6 mm, which were observed in most cases. These characteristics are highly accepted as sound standards to diagnose acute appendicitis and justify the usefulness of ultrasonography as an initial imaging device. The fact that appendicolith is found in a significant proportion of patients indicates that it is a causal factor of obstruction at the lumen and progression of the disease. Also the presence of the findings like periappendiceal fluid and abscess formation shows the capability of the ultrasonography not

only to detect early appendicitis but also to detect the complications. All in all, these findings support the idea that ultrasonography is sensitive and clinically useful in the identification of both common and complex cases of acute appendicitis.

Table 4 provides a summary of diagnostic performance of ultrasonography in the detection of acute appendicitis in the study population. Sensitivity of ultrasonography was established at 91.3% meaning that it has high potential of identifying the disease patient correctly. It had a specificity of 88.2 which indicates a high rate of ability to rule out patients not having

appendicitis. The positive predictive value (PPV) was 93.1 which implies that a high percentage of patients who were diagnosed positive on ultrasonography actually had the disease. The negative predictive value (NPV) was 85.0, which means that the majority of the patients who had a negative ultrasonography

outcome were disease-free. The total diagnostic correctness of ultrasonography was estimated as 90 percent. These parameters are graphically illustrated in Figure 4 that indicates clearly high sensitivity, PPV and general accuracy in comparison with slightly lower yet still significant specificity and NPV.

Table 4: Diagnostic Accuracy of Ultrasonography

Parameter	Value (%)
Sensitivity	91.3
Specificity	88.2
PPV	93.1
NPV	85.0
Accuracy	90

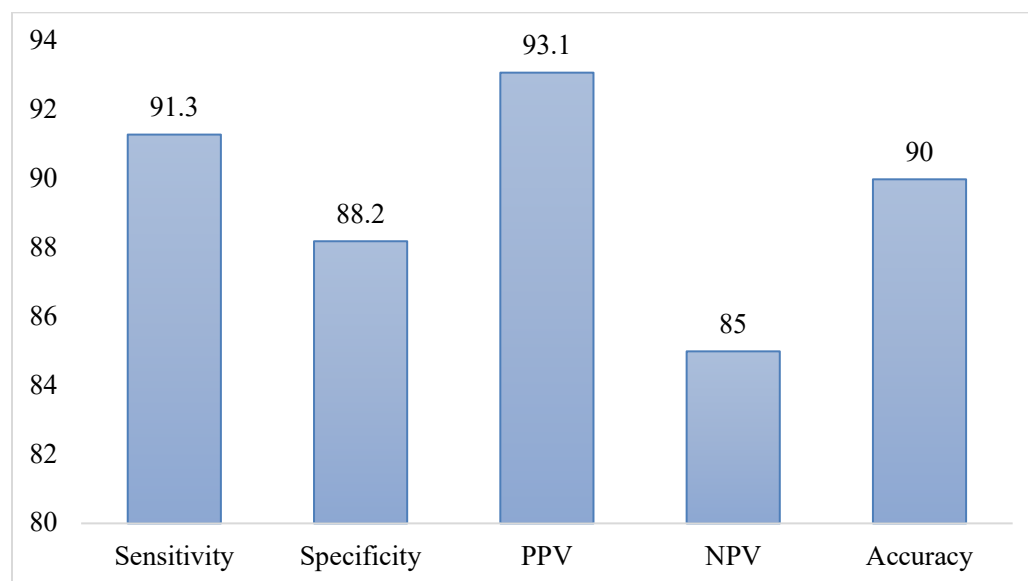


Figure 4: Visual Representation of Diagnostic Accuracy of Ultrasonography

The results reveal that ultrasonography is a very reliable diagnostic tool in acute appendicitis and the sensitivity and accuracy of ultrasound is excellent. Its high sensitivity (91.3) indicates that ultrasonography is effective in identifying true cases thus reducing missed diagnoses. Likewise, the high PPV (93.1) supports its applicability in the diagnosis of the disease in the positive case of the test result. The specificity (88.2) and NPV (85.0) are marginally lower; however, they all show good performance in the exclusion of appendicitis in patients who are not affected. These findings underscore the fact that ultrasonography can be an important means of minimizing unnecessary surgical practices like

negative appendectomies whilst ensuring prompt detection of the actual cases. In general, the evidence confirms the significance of ultrasonography as a reliable first-line mode of imaging, especially when quick, non-invasive, and affordable diagnosis is necessary.

Discussion

The current study compared ultrasonography with the early diagnosis of acute appendicitis and it proved that ultrasonography was a very reliable and effective diagnostic modality (Trout et al., 2012) [16]. The demographic results indicated that the highest prevalence rates of acute appendicitis were found in younger age

group, especially in 1020 years (26.7%), 3140 years (23.3%). Such age distribution is in line with the accepted epidemiological patterns, according to which acute appendicitis is predominant among the adolescents and young adults because of the high level of lymphoid tissue activity with the resultant luminal obstruction. The classical presentation, as observed in the current study, is also similar to the classical description with all patients (100%), experiencing right iliac fossa pain, nausea/vomiting (73.3%), fever (63.3%), and loss of appetite (56.7) (Mittal et al., 2013) [17]. These results support the criticality of clinical assessment in addition to indicating that symptom variability can be a difficult aspect to diagnose, and thus imaging modalities should be employed.

The ultrasonographic results in the current study are also in favor of its diagnostic value. The most common ones were a non-compressible appendix (82%) and appendiceal diameter exceeding 6 mm (80) which are both well-known leading indicators of acute appendicitis diagnosis (Scrimgeour et al., 2014) [18]. Additional evidence of the severity of the disease and complications was given by secondary findings like appendicolith (26.7%), periappendiceal fluid (20%), and abscess formation (10%). These findings can be compared with the past researches which underline the importance of ultrasonography in the diagnosis confirmation as well as the detection of complicated cases. The fact that the percentage of abscess formation is relatively lower makes it possible to believe that most of them in this study were diagnosed in an early stage, which emphasizes the importance of early imaging in preventing the evolution of the disease (Petroianu, 2012) [19].

The parameters of the diagnostic accuracy that were observed in the current research also confirm the usefulness of ultrasonography. Ultrasonography had a sensitivity of 91.3, specificity of 88.2 and an overall accuracy of 90 which made it very reliable in the detection of true cases as well as effectively ruling out non-cases. The high positive predictive value (93.1)

is a good predictive value that confirms the diagnosis, and the negative predictive value (85.0) indicates good ability to rule out the disease (Fathi et al., 2015) [20]. These results coincide with other literatures that have been reported in the past; ultrasonography is the first-line imaging modality, particularly in resource-limited setups. In addition, it is non-invasive, radiation-free, and cost-effective, which makes it especially applicable to large-scale clinical applications. In general, the article shows that ultrasonography plays a vital role in the early diagnosis, minimizing unnecessary surgical procedures, and enhancing patient outcomes in suspected acute appendicitis.

Conclusion

The current research indicates clearly that ultrasonography is a very effective, trustworthy, and non-invasive form of diagnosis used to detect acute appendicitis at an early stage. The evidence suggests that acute appendicitis is mainly seen in younger people, especially during the first 30 years of their lives and most of the cases are characterized by pain in the right iliac fossa with some symptoms like nausea, vomiting, fever and loss of appetite. Ultrasonographic analysis indicated that the most important diagnostic features such as non-compressible appendix and appendiceal diameter over 6 mm were found in most of the cases, which proves their significance as the main signs of the disease. Moreover, the ultrasonography was also useful in making secondary findings like appendicolith, periappendiceal fluid and abscess development thereby helping to detect complicated appendicitis. The sensitivity (91.3%), specificity (88.2%), and the overall diagnostic accuracy of ultrasonography (90) in this paper are important because they indicate the good diagnosis of the condition as well as ruling out the condition. These findings underscore its importance in decreasing diagnostic uncertainty, decreasing negative rates of appendectomy, and enabling prompt clinical decision-making.

References

1. Subash, K. C., De, A., Pathak, M., & Sathian, B. (2015). Diagnostic role of ultrasonography in acute appendicitis: a study at a tertiary care hospital. *Am J Public Health Res*, 3(5A), 23-28.
2. Debnath, J., Kumar, R., Mathur, A., Sharma, P., Kumar, N., Shridhar, N., ... & Khanna, S. P. (2015). On the role of ultrasonography and CT scan in the diagnosis of acute appendicitis. *Indian Journal of Surgery*, 77(Suppl 2), 221-226.
3. Pinto, F., Pinto, A., Russo, A., Coppolino, F., Bracale, R., Fonio, P., ... & Giganti, M. (2013). Accuracy of ultrasonography in the diagnosis of acute appendicitis in adult patients: review of the literature. *Critical ultrasound journal*, 5(Suppl 1), S2.
4. Parsijani, P. J., Zarandi, N. P., Paydar, S., Abbasi, H. R., & Bolandparvaz, S. (2013). Accuracy of ultrasonography in diagnosing acute appendicitis. *Bulletin of Emergency & Trauma*, 1(4), 158.
5. Hussain, S., Rahman, A., Abbasi, T., & Aziz, T. (2014). Diagnostic accuracy of ultrasonography in acute appendicitis. *Journal of Ayub Medical College Abbottabad*, 26(1), 12-17.
6. D'Souza, N., D'Souza, C., Grant, D., Royston, E., & Farouk, M. (2015). The value of ultrasonography in the diagnosis of appendicitis. *International journal of surgery*, 13, 165-169.
7. Jang, K. M., Lee, K., Kim, M. J., Yoon, H. S., Jeon, E. Y., Koh, S. H., ... & Choi, D. (2010). What is the complementary role of ultrasound evaluation in the diagnosis of acute appendicitis after CT?. *European Journal of Radiology*, 74(1), 71-76.
8. Bachar, I., Perry, Z. H., Dukhno, L., Mizrahi, S., & Kirshstein, B. (2013). Diagnostic value of laparoscopy, abdominal computed tomography, and ultrasonography in acute appendicitis. *Journal of Laparoendoscopic & Advanced Surgical Techniques*, 23(12), 982-989.
9. Bhangu, A., Søreide, K., Di Saverio, S., Assarsson, J. H., & Drake, F. T. (2015). Acute appendicitis: modern understanding of pathogenesis, diagnosis, and management. *The Lancet*, 386(10000), 1278-1287.
10. Schellekens, D. H., Hulsewé, K. W., van Acker, B. A., van Bijnen, A. A., de Jaegere, T. M., Sastrowijoto, S. H., ... & Derikx, J. P. (2013). Evaluation of the diagnostic accuracy of plasma markers for early diagnosis in patients suspected for acute appendicitis. *Academic Emergency Medicine*, 20(7), 703-710.
11. Aspelund, G., Fingeret, A., Gross, E., Kessler, D., Keung, C., Thirumoorthi, A., ... & Ruzal-Shapiro, C. (2014). Ultrasonography/MRI versus CT for diagnosing appendicitis. *Pediatrics*, 133(4), 586-593.
12. Park, J. S., Jeong, J. H., Lee, J. I., Lee, J. H., Park, J. K., & Moon, H. J. (2013). Accuracies of diagnostic methods for acute appendicitis. *The American Surgeon*, 79(1), 101-106.
13. Kim, C., Kang, B. S., Choi, H. J., Lim, T. H., Oh, J., & Chee, Y. (2015). Clinical application of real-time tele-ultrasonography in diagnosing pediatric acute appendicitis in the ED. *The American journal of emergency medicine*, 33(10), 1354-1359.
14. Sivitz, A. B., Cohen, S. G., & Tejani, C. (2014). Evaluation of acute appendicitis by pediatric emergency physician sonography. *Annals of emergency medicine*, 64(4), 358-364.
15. Zakaria, O., Sultan, T. A., Khalil, T. H., & Wahba, T. (2011). Role of clinical judgment and tissue harmonic imaging ultrasonography in diagnosis of paediatric acute appendicitis. *World Journal of Emergency Surgery*, 6(1), 39.
16. Trout, A. T., Sanchez, R., Ladino-Torres, M. F., Pai, D. R., & Strouse, P. J. (2012). A critical evaluation of US for the diagnosis of pediatric acute appendicitis in a real-life setting: how can we improve the diagnostic value of sonography?. *Pediatric radiology*, 42(7), 813-823.
17. Mittal, M. K., Dayan, P. S., Macias, C. G., Bachur, R. G., Bennett, J., Dudley, N. C., ... & Pediatric Emergency Medicine Collaborative Research Committee of the

- American Academy of Pediatrics. (2013). Performance of ultrasound in the diagnosis of appendicitis in children in a multicenter cohort. *Academic Emergency Medicine*, 20(7), 697-702.
18. Scrimgeour, D. S., Driver, C. P., Stoner, R. S., King, S. K., & Beasley, S. W. (2014). When does ultrasonography influence management in suspected appendicitis?. *ANZ journal of surgery*, 84(5), 331-334.
19. Petroianu, A. (2012). Diagnosis of acute appendicitis. *International journal of surgery*, 10(3), 115-119.
20. Fathi, M., Hasani, S. A., Zare, M. A., Daadpey, M., Hojati Firoozabadi, N., & Lotfi, D. (2015). Diagnostic accuracy of emergency physician performed graded compression ultrasound study in acute appendicitis: a prospective study. *Journal of ultrasound*, 18(1), 57-62.