



METRONIDAZOLE (1%) AND CHLORHEXIDINE (0.25%) GEL AS AN ADJUNCT TO SCALING AND ROOT PLANING IN THE TREATMENT OF MODERATE TO SEVERE CHRONIC PERIODONTITIS—A CLINICAL STUDY.

Dr. Huda Hussain¹, Prof.(Dr.) Suhail Majid Jan², Dr. Roobal Behal³

¹Postgraduate Scholar, Department of Periodontology, Government Dental College and Hospital, Srinagar, J&K, 190010.

²Head of Department, Department of Periodontology, Government Dental College and Hospital, Srinagar, J&K, 190010.

³Assistant Professor, Department of Periodontology, Government Dental College and Hospital, Srinagar, J&K, 190010.

Article Info: Received 10 April 2019; Accepted 10 May. 2019

DOI: <https://doi.org/10.32553/jbpr.v8i3.594>

Address for Correspondence: Dr. Huda Hussain, Postgraduate scholar, Department of Periodontology, Government Dental College and Hospital, Srinagar, J&K, 190010.

Conflict of interest statement: No conflict of interest

ABSTRACT:

Metronidazole and Chlorhexidine are commonly employed antimicrobial agents in the antinflective stage of periodontal therapy, used with the aim to achieve complete eradication of the pathogenic flora from the subgingival niches, in conjunction with professional debridement. This study was aimed to determine the adjunctive effect of a novel combination of metronidazole (1%) and chlorhexidine (0.25%) in a gel form for management of moderate to severe chronic periodontitis. Twenty subjects were included for a split mouth prospective study. Gingival index, Plaque Index, Bleeding scores and Probing depth were noted at baseline, 2 weeks and 1 month after scaling and root planing with or without an additional subgingival delivery of the antimicrobial gel. An improvement of periodontal health was seen after therapy, and the difference between the test and control sites was significant for sites with an initial probing depth of 6-8mm. However, for deeper pockets (>8mm) the difference was statistically non-significant. The reduction in bleeding score was sustained at the test sites throughout the study period. It was concluded that the adjunctive use of metronidazole (1%) and chlorhexidine (0.25%) gel could provide clinical benefit for the management of deep pockets upto 8mm of initial probing depth.

INTRODUCTION

Chronic periodontitis--an infectious disease caused by bacteria harboured in dental biofilms, is a global health burden. It affects all populations in the world, with a 20-50% worldwide prevalence (1), and is a leading cause of tooth loss and morbidity. Though its management primarily involves mechanical disruption and removal of plaque and its retentive factors, the adjunctive use of chemotherapeutic agents is justified to ensure complete eradication of the etiological microorganisms (predominantly gram negative anaerobes) from their subgingival and tissue niches

(2). A number of chemotherapeutic agents are used; mouthwashes and systemic antimicrobials being the most commonly prescribed. However, the use of these modalities is disadvantaged by the limited potential for pocket penetration, or the concern for antimicrobial resistance and systemic adverse effects.

These limitations are potentially overcome with local drug delivery into the periodontal pocket, which enables achievement of higher concentrations of drug in the affected area, without the concerns of systemic side effects. The local route of drug delivery can achieve 100 fold

higher concentration of an antimicrobial agent in the subgingival site, besides enabling the use of agents that cannot be administered systemically (2).

To be effective in the management of chronic periodontitis, a chemotherapeutic agent should be effective against obligate Gram negative anaerobes such as *Porphyromonas gingivalis*, *Fusobacterium*, *Tannerella forsythus*, and the Gram positive anaerobes such as *Peptostreptococcus* and *Campylobacter rectus* which are implicated in periodontal disease (3). Metronidazole is such an antimicrobial, and has been used successfully in the management of chronic periodontitis through the systemic and local route. It has a bactericidal effect against anaerobic organisms and some facultative anaerobic bacteria are also sensitive to its concentration after its local application (4). Similarly, chlorhexidine, which is considered gold standard chemotherapeutic agent(5), is highly effective against periodontopathic bacteria. Its affinity for hydroxyapatite and acidic salivary glycoprotein is accountable for its remarkable retention in the oral cavity which in turn has proved to be advantageous in the treatment of periodontal diseases (6).

With this background, the present study was designed to evaluate to adjunctive effect of a novel combination gel (Metronidazole 1% and Chlorhexidine 0.25%) along with professional scaling and root planing in the management of moderate to severe chronic periodontitis.

Material and Methods

The study was designed as a split mouth prospective clinical trial on twenty systemically healthy patients, within the age group of 35-65 years, diagnosed with moderate to severe periodontitis. They were included based on the presence of two or more non- adjacent sites with a probing depth \geq 5mm, and bleeding on probing. Exclusion criteria included pregnant/lactating female, systemic condition/ medication that could affect gingival bleeding and health, the use of systemic antibiotics during the study and previous or current chlorhexidine mouthwash use.

Treatment

The patients underwent scaling and root planing in 1-2 sessions after the antimicrobial gel containing

1% Metronidazole and 0.25% chlorhexidine (Metrohex, Dr. Reddy's Lab, India) was administered subgingivally in the affected sites of one quadrant. Subgingival delivery was performed with a 2 ml disposable syringe with a blunt needle bent at its shank by 130° and procedure continued until the pocket was completely filled. Care was taken to apply the gel without traumatizing or damaging the periodontal tissues. Control sites in the opposite quadrant were irrigated with normal saline. The patients were advised not to eat hard food that could traumatize the gingiva. They were instructed to brush twice daily using a soft tooth brush with the bass technique and any proprietary toothpaste. They were also asked to refrain from using any mouthwash during the study.

Data Collection and statistical analysis

Gingival index (7), Plaque index (8), and quadrant wise bleeding on probing score (%age of bleeding sites) were assessed at baseline, 2 weeks and 1 month after therapy. Probing Pocket Depth (deepest measurement at four sites) was measured at baseline and 1 month.

Statistical analysis was done using SPSS for windows (version 20). Student's independent t-test was used to compare the mean gingival index and probing depth. Bleeding on probing scores were subjected to paired t-test to assess significance of changes over time. A P-value of <0.05 was considered significant.

Results

All sites healed uneventfully. No adverse effect or abscess formation occurred in any of the sites. Patients did not report any discomfort or taste alterations with the use of antimicrobial gel. A significant improvement in the gingival health of the subjects was noted following therapy, with better results for the sites treated with the antimicrobial gel. Statistically significant difference was observed for gingival index and probing depth, between the control and treated sites in pockets deeper than 6-8mm at baseline (Fig. 1&2). Bleeding on probing scores also reduced in both the groups, however, the quadrants treated with the antimicrobial gel maintained significantly lower scores at month (Fig 3).

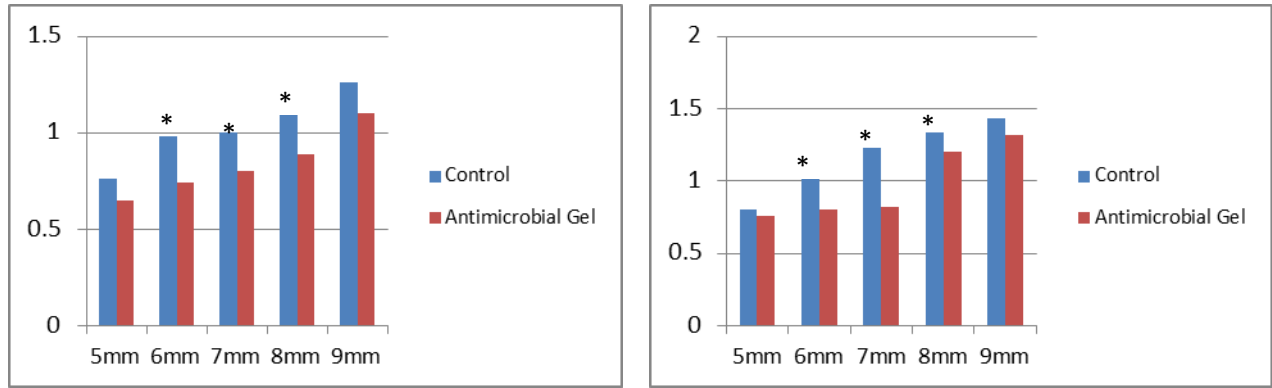


Fig. 1: Gingival index at 2 weeks and 1 month. * Denotes statistically significant at P<0.05

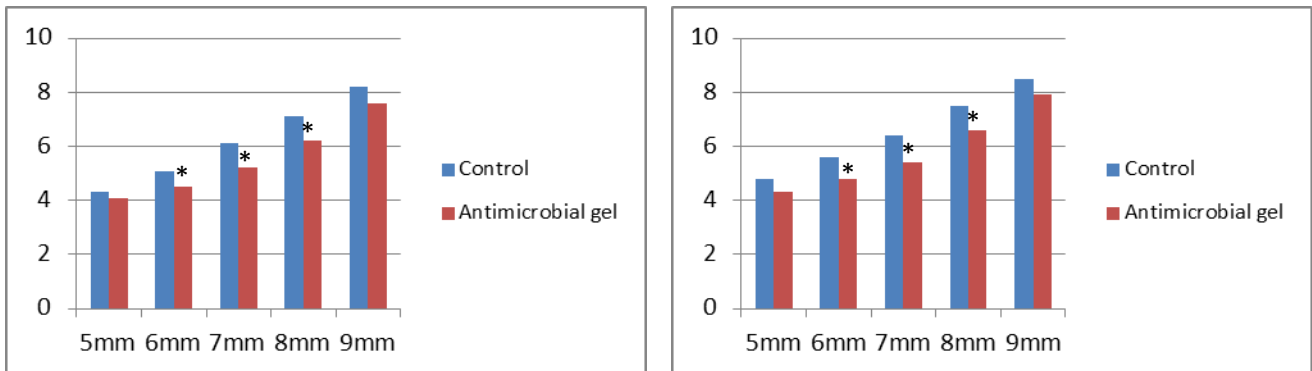


Fig. 2: Mean Probing Depth (mm) at 2 weeks and 1 month. * Denotes statistically significant at P<0.05

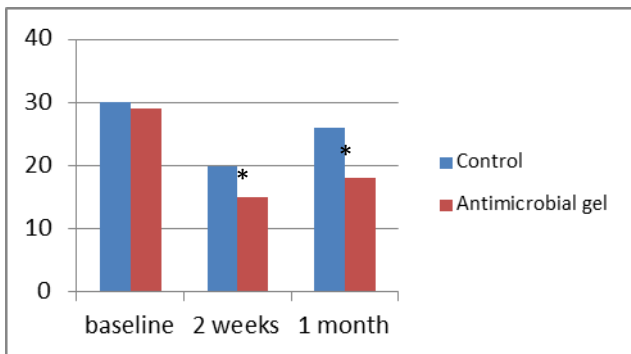


Fig. 3: Bleeding score (%) of quadrants at 2 weeks and 1 month. * Denotes statistically significant at P<0.05

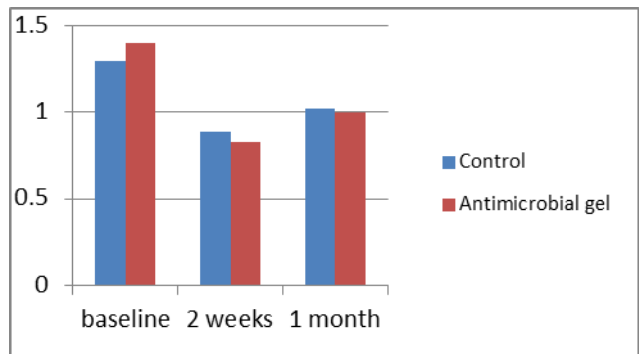


Fig. 4: Plaque index of quadrants at 2 weeks and 1 month. * Denotes statistically significant at P<0.05

Discussion

Conventional modalities for management of moderate to severe periodontitis consist of nonsurgical anti-infective therapy and surgical flap debridement or pocket reduction procedures (2). Within this spectrum, antimicrobials play an adjunctive role to aid in the control of the initial/recurrent infection. Local delivery of

antimicrobials is indicated when only a few sites in the mouth present with deep pockets >5mm (9). In the present study, the subjects presented with localised moderate to severe periodontitis with initial probing depths ranging from 5-9mm, and hence this treatment was considered prior to surgery.

A substantial improvement in gingival health and tissue consistency was noted in all the sites following treatment, as evidenced by the reduction in probing depth and gingival index throughout the study. This can be ascribed to the effects of thorough mechanical debridement and subsequent plaque control by the patients. Moreover, for pockets of 6-8mm initial probing depth, a significant decrease in probing depth and gingival index was noted at the sites treated with metronidazole-chlorhexidine gel. Both these antimicrobial agents are known to be highly effective against periodontopathic bacteria, with metronidazole acting against anaerobes, and chlorhexidine against gram positive and negative aerobes and facultative anaerobes (4). As the redox potential consistently decreases going deeper subgingivally (9), an active 'anti-anaerobic' antimicrobial, such as the nitroimidazoles (metronidazole, ornidazole, satrozole), is indicated for complete removal of microbes from deep pockets. Similar results have been reported with the use of ornidazole by Bashir et al.(10). On the other hand, the early recolonization of very deep pockets (~9mm) is favored due to the inaccessibility of routine plaque control measures (4), and hence, the initial improvement seen with treatment could not be sustained for longer periods.

Bleeding scores were assessed as an indication of disease activity; periodontal stability being predicted by the absence of bleeding (11). It was seen the initial reduction seen on bleeding scores was sustained for the entire study period for quadrants treated with the antimicrobial gel. It is known that chlorhexidine has an inherent substantivity (4), and an ability to persist on tooth surface for long periods. This might have perhaps contributed to the control of pathogenic flora in deep pockets, resulting in lesser bleeding scores at the treated sites. Further microbiological studies are needed to confirm these findings.

Conclusion

Within the limitations of this study, deep pockets in patients with localized moderate-severe periodontitis were found to respond favourably to the use of 1% metronidazole+ 0.025% chlorhexidine gel, with a reduction in probing depth and bleeding scores. The treatment can be

effectively used for initial infection control therapy in pockets of 6-8mm, whereas, deeper pockets may still require surgical intervention. Further studies with a longer follow up are implicated to evaluate the long term efficacy of this novel antimicrobial combination.

References

1. Nazir MA. Prevalence of periodontal disease, its association with systemic diseases and prevention. *International journal of health sciences*. 2017 Apr;11(2):72.
2. Lang NP, Lindhe J, editors. *Clinical periodontology and implant dentistry*, 2 Volume Set. John Wiley & Sons; 2015 Mar 25.
3. Greenstein G, Polson A. The role of local drug delivery in the management of periodontal diseases: A comprehensive review. *J Periodontol* 1998;69:507-20.
4. Clay BW, Katherine K, Baehni P. Chemotherapeutics: antibiotics and other antimicrobials. *Periodontol* 2000 2004; 36: 146- 165.
5. Jones CG. Chlorhexidine:is it gold standard? *Periodontology* 2000 1997;15: 52-62
6. Divya PV, K Nandakumar. Local drug deliveryPeriodol in periodontics. *Tren Bio Art Org*.2006; 19:78-80
7. Löe H, Silness J. Periodontal disease in pregnancy I. Prevalence and severity. *Acta odontologica scandinavica*. 1963 Jan 1;21(6):533-51.
8. Silness J, Löe H. Periodontal disease in pregnancy II. Correlation between oral hygiene and periodontal condition. *Acta odontologica scandinavica*. 1964 Jan 1;22(1):121-35.
9. Newman MG, Takei H, Klokkevold PR, Carranza FA. *Carranza's clinical periodontology*. Elsevier health sciences; 2011 Feb 14.
10. Bashir B, Jan SM , Behal R. 'Evaluation of Ornidazole Gel as an Adjunct to Non Surgical Periodontal Therapy in Chronic Periodontitis Patients', 2019International Journal of Current Advanced Research, 08(03), pp. 17797-17799.
11. Lang NP, Joss A, Orsanic T, Gusberti FA, Siegrist BE. Bleeding on probing. A predictor for the progression of periodontal disease?. *Journal of clinical periodontology*. 1986 Jul;13(6):590-6.

